Pavol Jozef Šafárik University in Košice

Faculty of medicine

Examination methods and injection technique in orthopaedics

MUDr. Ahmad Gharaibeh, PhD., MPH

Doc. MUDr. Marek Lacko, PhD.

Košice 2021

Acknowledgement

I would like to express my sincere gratitude to my colleagues and thank them for his patients, advise me all along. For the supporting of my monograph.

Great thanks to our parents and families for their love, supports, for showing faith in me and for always supporting me.

Authors

Examination methods and injection technique in orthopaedics
Academic textbook

Authors:

MUDr. Ahmad Gharaibeh, PhD., MPH
Doc. MUDr. Marek Lacko, PhD.
Faculty of Medicine, Pavol Jozef Šafárik University in Košice

Reviewers:

Doc. MUDr. Gabriel Vaško, CSc.
Faculty of Medicine, Pavol Jozef Šafárik University in Košice

MUDr. Ahmed Al Wadiya
University Hospitals of Derby and Burton

The authors are responsible for the content of the publication

Available at: www.unibook.upjs.sk
Publication date: 27.04.2021

ISBN 978-80-8152-989-4 (e-publication)

Contents

1. History (Gharaibeh) …….. 7

2. Examination methods in orthopaedics (Gharaibeh) ……. 8

2. 1. Medical History of patient …….. 8

2.1.1. The chief complaint ……10

2.1.2. History of the present illness ……..10

2.1.3. Review of systems …… 10

2.1.4. Impact of treatment …….. 12

2.1.5. Computer-assisted history taking…… 12

2.1.6. Status present localis …….. 13

2.1.7. Introduction to examination ……. 13

2.1.8 Alignment, axial deformities of the limbs …….. 13

2.1.9. Limb length assessment …… 13

2.1.10. Measurement of limb circumference …….. 13

2.2. Physical Examination of the spine (Gharaibeh) …….. 14

2.2. 1. Inspection ……14

2.2.2. Palpate ……14

2.2.3. Movement ……14

2.2.4. Special Tests …….. 16

2.3. Upper limb examinations (Gharaibeh) ……18

2.3.1. Shoulder ……18

2.3.1.1. Inspection ……18

2.3.1.2. Palpate ……18

2.3.1.3. Movement ……..18

2.3.1.4. Special Tests …….. 20

2.3.2. Elbow ……26

2.3.2.1. Introduction ……..26

2.3.2.2. Range of motion of the elbow …….26

2.3.2.3. Orthopaedic Special Tests for the Elbow ……. 26

2.3.3. Wrist and Hand ……... 28

2.3.3.1. Introduction …… 28
2.3.3.2. Inspection …….28
2.3.3.3. Palpation ……..…….29
2.3.3.4. Movement …….30
2.3.3.5. Special Tests …… 32

Lower limb examinations (Gharaibeh) ……34
2.3.4. Hip ……. 34
2.3.4.1. Introduction ……. 34
2.3.4.2. Inspection …….. 34
2.3.4.3. Palpate …… 35
2.3.4.4. Movement …….. 35
2.3.4.5. Orthopaedic Special Tests for the Hip …….. 36
2.3.4.6. Special tests for new born ……. 37

2.3.5. Knee …….. 39
2.3.5.1. Introduction …….. 39
2.3.5.2. Inspection …….. 39
2.3.5.3. Palpate …….41
2.3.5.4. Assessing for Joint Effusion ……. 41
2.3.5.5. Movement ……41
2.3.5.6. Special Tests for the knee……. 42

2.3.6. Ankle …… 46
2.3.6.1. Introduction …….. 46
2.3.6.2. Inspecte …….. 46
2.3.6.3. Palpate…….46
2.3.6.4. Movement ……46
2.3.6.5. Orthopaedic Special Tests for the Ankle……. 47

2.3.7. Foot ……..49
2.3.7.1. Introduction …… 49
2.3.7.2. Inspection …… 49
2.3.7.3. Palpate …….. 49
2.3.7.4. Movement …….. 49

2.3.7.5. Podoscopic (foot print) test ……. 49

2.4. Complete the Examination …… 50

2.5. Orthopaedic Diagnostic Tests …….. 51
2.5.1. Laboratory Studies …… 51
2. 5.2. Radiography (X-ray) …….. 54
2.5.2.1 Special views X-ray …….. 55
2.5.3. Bone Scan ……. 56
2.5.4. Computed Tomography (CT scan) ……. 57
2.5.3.2 CT Angiography and CT Perfusion Imaging ……. 57
2.5.3.2.1. Technique ……. 58
2.5.3.3. Staging of Primary Tumours …… 58
2.5.4.1. Intrathecal Contrast Enhanced CT Scan …… 60
2.5.5. Arthrography …… 61
2.5.6. Discography ……. 62
2.5.7. Magnetic Resonance Imaging (MRI) …… 62
2.5.8. Ultrasonography ……. 63
2.5.8.1. Doppler Ultrasound ……. 64
2.5.9. Dual-Photon Absorptiometry …… 65
2.5.9.1. Dual-Energy X-ray Absorptiometry ……. 65
2.5.8.2. Peripheral Bone Density Testing ……. 66
2.5.9.3. Quantitative Computed Tomography ……. 66
2.5.10. Electromyography …… 66
2.5.10.1. Nerve Conduction Study (NCS) ……. 67
2.5.11. Flexibility Tests ……... 67
2.5.12. Joint Aspiration and Analysis …… 68
2.5.13. Muscle Tests …….. 68
2.5.14. Stress Tests …… 69
2.5.15. Scintigraphy of the Musculoskeletal System…… 69

2.6. Histology and cytology investigations …….. 75

2.7. Diagnostic Arthroscopy ……. 76

2.8. Sample of patient's documentation (state exam) ……. 77

3. Principles of Injection in Orthopaedic surgery (Joints and soft tissue) (Lacko) …... 79

3.1. Indications for joint injection …….. 79

3.2. Indications for soft tissue injection ….. 79

3.3. Before Joint and soft tissue injection ……80

3.4. Procedure of Joint and soft tissue injection ……. 80

3.5. Arthrocentesis Joint Aspiration ……... 81

3.6. Image-Guided Biopsy ……. 82

3.7. Cautions ……. 84

3.8. Patient advice ……..84

3.9. Mistakes in joint and soft tissue injections …….. 85

3.10. Side-effects …….. 85

3.10.1. Local Side-effects …….. 8

53.10.2. Systemic Side-effects …...85

3.11. Contra-indications …… 85

References ……. 86

List of figures ……. 87

1. **History:**

The medical history and physical examination were supremely important to diagnosis before advanced health technology was developed, and even today, despite advances in medical imaging and molecular medical tests, the history and physical examination remain indispensable steps in evaluating any patient. Before the 19th century, the history and physical examination were nearly the only diagnostic tools the physician had, which explains why tactile skill and ingenious appreciation in the exam were so highly valued in the definition of what made for a good physician. Even as late as 1890, the world had no radiography or fluoroscopy, only early and limited forms of electrophysiologic testing, and no molecular biology as we know it today. Ever since this peak of the importance of the physical examination, reviewers have warned that clinical practice and medical education need to remain vigilant in appreciating the continuing need for physical examination and effectively teaching the skills to perform it; this call is ongoing, as the 21st-century literature shows.

2. Examination methods in orthopaedics

2.1. Medical history of patient:

3. The medical history or anamnesis (from Greek: “aná” - open, and “mnesis” - memory) of a patient is information gained by a physician by asking specific questions, either of the patient or of other people who knows the person and can give suitable and adequate information, with the aim of obtaining information useful in formulating a diagnosis and providing medical care to the patient. The medically relevant complaints reported by the patient or others familiar with the patient are referred to as symptoms, in contrast with clinical signs, which are ascertained by direct examination on the part of medical personnel. Most health encounters will result in some form of history being taken. Medical histories vary in their depth and focus. For example, an ambulance paramedic would typically limit their history to important details, such as name, history of presenting complaints, allergies, etc. In contrast, a psychiatric history is frequently lengthy and in depth, as many details about the patient's life are relevant to formulating a management plan for a psychiatric illness.
4. The medical history is a longitudinal record of what has happened to the patient since birth. It chronicles diseases, major and minor illnesses, as well as growth landmarks. It gives the clinician a feel for what has happened before to the patient. As a result, it may often give clues to the current disease state. It includes several subsets detailed below.
5. Identification and demographics: name, age, address, telephone number, insurance.
6. Demographics include patient information that is not medical in nature. It is often information to locate the patient, including identifying numbers, addresses, and contact numbers. It may contain information about race and religion as well as workplace and type of occupation. It also contains information regarding the patient's health insurance. It is common to also find emergency contact information located in this section of the medical chart.
7. Height, weight, body mass index (BMI), temperature, blood pressure, heart rate.
8. Past medical history (PMH): including major illnesses, chronic medical illness past and on-going illnesses (e.g. diabetes mellitus, hypertension, ischemic heart disease, tuberculosis, tumours).
9. Surgical history: the surgical history is a chronicle of surgery performed for the patient. It may have dates of operations, operative reports, and/or the detailed narrative of what the surgeon did.
10. Obstetric history: the obstetric history lists prior pregnancies and their outcomes. It also includes any complications of these pregnancies.
11. Psychiatric illness.

12. Medications: the medical record may contain a summary of the patient's current and previous medications, regular and acute medications (including those prescribed by doctors, and others obtained over-the-counter or alternative medicine).
13. Allergies:

- Known allergy to medications
- Allergies to food
- Allergies to latex
- Allergies to environmental factors

14. Family history: the family history lists the health status of immediate family members as well as their causes of death (if known). It may also list diseases common in the family or found only in one sex or the other. It may also include a pedigree chart. It is a valuable asset in predicting some outcomes for the patient.
15. Social history: the social history is a chronicle of human interactions. It tells of the relationships of the patient, his/her careers and practice, and religious practice. It is helpful for the physician to know what sorts of community support the patient might expect during a major illness. It may explain the behaviour of the patient in relation to illness or loss. It may also give clues as to the cause of an illness (e.g. occupational exposure to asbestos). Social history (medicine) – including living arrangements, occupation, marital status, number of children.
16. Home circumstances: knowledge of the home circumstances is vital when dealing with the elderly. Problems are inevitable if the patient cannot climb stairs and the only lavatory is on the top floor. If the patient can’t walk out of the house, who will do the shopping?
17. These mundane details have no bearing on the diagnosis or the operations that are technically possible but they have everything to do with selecting the right treatment for the individual patient.
18. Environmental pathogens through recreational activities or pets.
19. Recent foreign travel.
20. Habits: various habits which impact health, such as tobacco use, alcohol intake, exercise, and diet are chronicled, often as part of the social history. This section may also include more intimate details such as sexual habits and sexual orientation.
21. Immunization history: the history of vaccination is included. Any blood tests proving immunity will also be included in this section.
22. Growth chart and developmental history: for children and teenagers, charts documenting growth as it compares to other children of the same age is included, so that health-care providers can follow the child's growth over time. Many diseases and social stresses can affect growth, and longitudinal charting can thus provide a clue to underlying illness. Additionally, a child's

behaviour (such as timing of talking, walking, etc.) as it compares to other children of the same age is documented within the medical record for much the same reasons as growth.

23. **Occupation:** find out not only the name of the patient's job but also exactly what it involves. One driver may spend the entire day sitting behind the steering wheel but another will have to load and unload the vehicle, which entails a great deal of heavy physical work. A lathe operator who stands for most of the day could not work with a painful foot but could manage with a stiff knee, while a motor mechanic could tolerate a painful foot but a stiff knee would make it impossible to work in tight corners or under vehicles. The loss of the terminal phalanx of the ring finger would be of little consequence to a labourer, but disastrous to a musician.

2.1.1. **The chief complaint (CC)**: The major health problem or concern, and its time course (e.g. back pain, hip pain or fowling down).

2.1.2. **History of the present illness (HPI):** Details about the complaints, enumerated in the CC. (Also often called 'History of presenting complaint' or HPC.)

2.1.3. **Review of systems (general status) (ROS):** systematic questioning about different organ systems

- **Head:** Shape of the head is plagiocephalic. No scar was detected during inspection. Big fontanelle size is 0,5x1 cm Face: The eyes are symmetrical, without any sign of strabismus. There was no oedema in the eyelids. The conjunctiva is pink without any inflammation. Bulbs are at median position with moving ability to all directions. The sclera is white without signs of jaundice. Pupils are isochoric. Direct and bilaterally photoreaction is consensual. There is normal bilateral innervation of the facial nerve (7th cranial nerve). The patient was able to smile symmetrical while no muscle weakness was detected during facial expression. Ears and nose do not present either discharge or deformity. Oral cavity: The mucous membrane is pink and well hydrated. The tongue is pink without any signs of dehydration or inflammation or presence of mucous plagues. Tonsils were symmetrically medium - sized without signs of inflammation (redness and oedema). Oropharynx did not present any sign of inflammation.
- **Nervous system** (Headache, loss of consciousness, dizziness and vertigo, speech and related functions like reading and writing skills and memory).
- **Cranial nerves symptoms** (Vision, amaurosis, diplopia, facial numbness, deafness, oropharyngeal dysphagia, limb motor or sensory symptoms and loss of coordination).
- **Cardiovascular system** (chest pain, dyspnoea, ankle swelling, palpitations) are the most important symptoms and you can ask for a brief description for each of the positive symptoms.
- **Respiratory system** (cough, haemoptysis, epistaxis, wheezing, pain localized to the chest that might increase with inspiration or expiration). **Chest:** Symmetrical, with epigastric retraction

during breathing. Auscultation reveals prolonged expiration, wheezing and expiratory stridor. During heart auscultation, the 3rd heart sound was audible. No heart murmur was audible.

- **Abdomen:** The abdomen is symmetrical without any detectable protrusion and at the same level with the chest (niveau). The abdomen is soft and non-resistant during palpation without any pain and tenderness. The percussion sound was tympanic. There is no organomegaly (hepatomegaly, splenomegaly). During palpation any palpable mass was detected. Tapotement examination was negative.
- **Gastrointestinal system** (change in weight, flatulence and heartburn, dysphagia, odynophagia, hematemesis, melena, hematochezia, abdominal pain, vomiting, bowel habit).
- **Genitourinary system** (frequency in urination, pain with micturition (dysuria), urine color, any urethral discharge, altered bladder control like urgency in urination or incontinence, menstruation and sexual activity).
- **Endocrine system** (weight loss, polydipsia, polyuria, increased appetite (polyphagia) and irritability).
- **Skin** (any skin rash, recent change in cosmetics and the use of sunscreen creams when exposed to sun, Turgor, discolouration) (See figure No. 1, 2).

Figure No. 1 discolouration and skin defect

Figure No.2 Inflammation

2.1.4. **Impact of treatment:** Treatment always disturbs the patient's life, sometimes seriously. To suggest an operation that would make a self-employed tradesman unable to work for 2 or 3 months needs careful thought. Timing is also important: to be rendered unfit during the harvest could bring financial ruin to a single-handed arable farmer for whom the quietest period of the year is at Christmas; on the other hand, shopkeepers need to be at their fittest during the Christmas period and, except in a tourist centre, would probably choose August for operation.

2.1.5. **Computer-assisted history taking:**

Computer-assisted history taking systems have been available since the 1960s. However, their use remains variable across healthcare delivery systems.

One advantage of using computerized systems as an auxiliary or even primary source of medically related information is that patients may be less susceptible to social desirability bias. For example, patients may be more likely to report that they have engaged in unhealthy lifestyle behaviours. Another advantage of using computerized systems is that they allow easy and high-fidelity portability to a patient's electronic medical record. Also an advantage is that it saves money and paper.

One disadvantage of current medical history systems is that they cannot detect non-verbal communication, which may be useful for elucidating anxieties and treatment plans. Another disadvantage is that people may feel less comfortable communicating with a computer as opposed to a human.

2.1.5. Status present localis: Musculoskeletal system (any bone or joint pain accompanied by joint swelling or tenderness, aggravating and relieving factors for the pain and any positive family history for joint disease).

1. **Spine**
2. **Limbs**

2.1.7. **Introduction to examination:**

Introduce yourself to the patient

- Wash your hands
- Briefly explain to the patient what the examination involves
- Ask the patient to remove their top clothing, exposing the entire spine
- Offer the patient a chaperone, if necessary

Always start with inspection and proceed as below unless instructed otherwise; be prepared to be instructed to move on quickly to certain sections by the examiner.

2.1.8 Alignment and axial deformities of the limbs

Measurement of the angle formed between the mechanical axis and the anatomic axis is used to determine the axial alignment of the limb. There is acceptable normal value for this angle valgus or varus deformation in upper and lower, rotational angles and non-complete range of motions, all angels we can measure them by goniometers.

2.1.9. **Limb length assessment**

True length is the measurement taken from the anterior superior iliac spine to the tip of medial malleolus while both lower limbs are in identical positions and the pelvis is square.

True length upper limb measurements were performed on each upper extremity using a standard tape measure: the distance from the tip of the acromion to the elbow flexion crease (arm length), the distance from the elbow flexion crease to the wrist flexion crease (forearm length), and from acromion to the tip of third finger in supine position.

2.1.10. **Measurement of limb circumference**

Mark the Measuring Site, Measure Circumference by tape and make the same on other limbs, then compare.

2.2. **Examination of the Spine**

2.2.1. **Inspection**

- Assess spinal alignment from an anterior, lateral, and posterior view. Check for the presence of normal spinal curvatures:
- Excess lordosis
- Excessive kyphosis
- Scoliosis
- Check for:
  1. Skin changes, redness, pallor
  2. Scars
  3. Swelling
  4. Masses
  5. Discolouration

2.2.2. **Palpate**

- Palpate each spinous process for tenderness
- Start with the atlanto-occipital joint and finishing at the sacroiliac joint
- Palpate the trapezius and paraspinal muscles, assessing for muscle bulk, spasm and tenderness
- Gently percuss down the spine for pain or tenderness
- Sensitive for infection, trauma or neoplasm
- Feel for temperature down the spine

2.2.3. **Movement**

Range of Motion Measuring by using a device called a Goniometer. A goniometer is a metal or plastic handheld device with two arms or goniometer smart phone application (see shape No.2).

Check each part of the spine systematically

- Cervical spine:
- Flexion (‘chin-to-chest’) and extension (‘look at the ceiling’)
- Lateral rotation to each side (“look over your shoulder”)
- Lateral flexion to each side (“bring your ear down to your shoulder”)

The cervical spine's range of motion is approximately 80° to 90° of flexion, 70° of extension, 20° to 45° of lateral flexion, and up to 90° of rotation to both sides (See figure No. 3)

- Thoracolumbar spine:
- Flexion, ask patient to touch their toes (see Schober’s test)
- Extension (support the patient so they don’t fall)
- Lateral flexion, ask patient to run their arms down the side of each leg in turn
- Lateral rotation, sit the patient on the bed (to fix the pelvis) and cross their arms, then ask to rotate from one side to the other

From neutral, the thoracic spine can flex to approximately 35 ° of additional flexion. Thus, in full flexion, the thoracic spine demonstrates up to 75 ° of flexion. Conversely, the thoracic spine only moves 20 ° to 25 ° of extension.

The absolute ROM and percentage of full active lumbar spinal ROM was 3 to 49 degrees and 4% to 59% (median: 9 degrees/11%) for flexion/extension, 2 to 11 degrees and 6% to 31% (6 degrees/17%) for lateral bending, and 2 to 7 degrees and 6% to 20% (5 degrees/13%) for rotation (See figure No. 4, 5, 6)

Figure No. 3 Lateral flexion of cervical spine to the left side

Figure No. 4 Lateral flexion of lumbar spine to the right side

Figure No. 5, 6 Sagittal movements of lumbar spine flexion and extension

2.2.4. Special Tests

- Ask the patient to squat and rise from squatting
- Assesses L3 (knee extensors)
- Ask patient to stand on their heels
- Assesses L4 (ankle dorsiflexors)
- Ask the patient to lift their big toes off the ground
- Assesses L5 (long toe extensors)
- Ask patient to stand on their tip toes
- Assesses S1 (ankle plantar flexors)
- Schober's test to formally assess the amount of lumbar flexion:
- Mark 10cm superiorly from the 'Dimples of Venus' and 5cm inferiorly. Place your fingers on these areas. Ask patient to touch their toes
- This gap between the 2 marks (which is currently 15cm), should increase by >5cm. Anything less than this indicates reduced lumbar flexion.
- Sciatic nerve stretch test (also called the straight leg raise test)
- Looks for radiculopathy of the nerve roots of the sciatic nerve (L4-S3). Patient lies supine and ask them to straight leg raise (Lasegue's Test)
- If the patient has sciatic nerve root radiculopathy they will get shooting pains which on minimal elevation which can be exacerbated by ankle dorsiflexion (stretching the sciatic nerve further) (Pragard's Test)

2.3. Upper limb examinations

2.3.1. Shoulder

Because of its great mobility and range of motion (ROM) the shoulder girdle is very prone to instability. As a result, many of these tests are related to testing the stability of the shoulder. Another common problem that many of these tests address is impingement or compressions of structures underneath the bony prominences of the shoulder. There are also tests that focus on stressing the various soft tissues of the shoulder including nerves, ligaments, tendons and muscles.

There are multiple joints that make up the shoulder complex. Different tests focus on the different joints. The largest joint in the shoulder is the glenohumeral joint. However, other joints targeted by the below tests include the A-C or acromioclavicular joint and the S-C or sternoclavicular joint. The articulation of the shoulder blade or 'scapula' with the rib cage is also considered a joint and is targeted by some of the special tests.

2.3.1.1. **Inspection**

Assess for

- Skin changes (e.g. erythema that may indicate septic arthritis)
- Scars (i.e. previous surgery)
- Swelling (suggesting potential joint effusion)
- Masses
- Discolouration
- Deformations

2.3.1.2. **Palpate**

- Check temperature
- Compare both sides
- Feel for muscle bulk
- Especially the deltoid, supraspinatus, and infraspinatus
- Feel for bone and joint tenderness, working systematically from medial to lateral:
- SCJ → clavicle → ACJ → coracoid process → acromion process → scapular spine → greater tuberosity of the humerus.

2.3.1.3. **Movement**

- Check active movements
- Flexion and Extension
- Abduction and Adduction

- Observe the patient from the back to note symmetry and smoothness of scapula-thoracic movements
- Internal rotation (hands behind back) and external rotation (hands behind head)

Range of Motion Measuring by using a device called a goniometer. A goniometer is a metal or plastic handheld device with two arms (See figure No. 7).

.

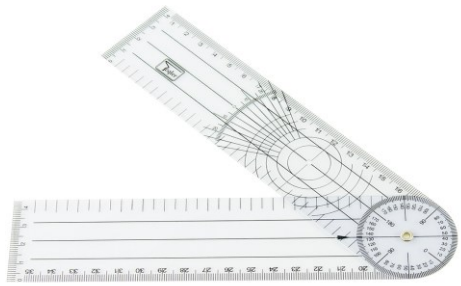

Figure No. 7 Goniometer

Flexion 0 to 180 degrees

- Extension 0 to 50 degrees
- Abduction 0 to 90 degrees
- Adduction 90 to 0 degrees
- Lateral rotation 0 to 90 degrees
- Medial rotation 0 to 90 degrees
- Assess rotator cuff muscles
- Supraspinatus (by 'Empty Can' test)
- Shoulder flexed forwards to 90 degrees and slightly abducted with internal rotation so that thumb is pointing to the ground (as if emptying a can) and attempting to continue bringing the arm up against resistance.
- Subscapularis (by Gerber's 'Lift Off' test)
- Hand placed in the small of the back with palm facing outwards and attempt to push against the examiner's hand.
- Infraspinatus
- Assess resisted external rotation. Ask the patient to tuck their elbows into sides and externally rotate their forearm against your hand.
- Teres Minor (by 'Hornblowers tests')

- Abduct the shoulder to 90 degrees and flex the elbow to 90 degrees and attempt to externally rotate against resistance (See figure No. 8, 9).

.

Figure No. 8, 9 Shoulder movements

2.3.1.4. Special Tests (this part just for extra knowledge)

- 'Painful Arc' test (positive in supraspinatus tendinopathy, subacromial bursitis, and ACJ osteoarthritis)
- When the patient abducts their shoulder, the pain is worst during the middle arc
- Scarf Test (positive in ACJ osteoarthritis)

Ask the patient to place the hand of the side you are examining on the contralateral shoulder and then push the elbow superiorly to compress the acromion against the lateral end of the clavicle

- Hawkins-Kennedy test (positive in shoulder impingement)

Flex the shoulder to 90owith the elbow flexed to 90o. Internally rotate the shoulder – pain is indicative of impingement.

- Neer test (positive in for shoulder impingement)

Maximally internally rotate the shoulder and the passively forward flex it. Pain is indicative of impingement.

- Winging of the scapula (positive in long thoracic nerve palsy)

Get the patient to push hand against a wall whilst standing and look for lifting of the scapula off the thoracic wall due to weak serratus anterior muscle

- Acromioclavicular (AC) Joint Distraction Test (Bad Cop Test): Method Examiner gently pulls down on the arm with the elbow flexed at 90º.
- Acromioclavicular (AC) Shear Test: The patient is in sitting position while the examiner cups his or her hands over the deltoid muscle with one hand on the clavicle and the other on the spine of the scapula. The examiner then squeezes the heels of the hand together. Abnormal movement is a positive test.
- Adson's Test / Adson's Maneuver – Thoracic Outlet Syndrome: In standing palpate the radial pulse on the affected side with the elbow fully extended. Have the patient rotate their head to the side being tested and extend the neck. Next, abduct, extend, and laterally rotate the shoulder. From this position, have the patient take a deep breath and hold. Assess the pulse response. A positive test is a decrease in pulse vigor from the starting position to the final position.
- Allen Test: for vascular insufficiency, is a medical sign used in physical examination of arterial blood flow to the hands.
- Anterior Drawer Test: The patient is in a supine position and the affected shoulder over the edge of the table. The patient's arm should be relaxed. Position the arm in a combined midrange abducted position with forward flexion and lateral rotation. The stabilising hand is placed on the scapula so that the fingers and thumb secure the scapula at the spine of the scapula and the coracoid. The patient's arm is pulled anteriorly to apply a gliding force to the glenohumeral joint. If an audible click is heard during the movement, the glenoid labrum may be torn, or the joint may be sufficiently lax to allow the humeral head to glide over the glenoid labrum rim.
- Anterior Slide Test / Keibler Test – for SLAP lesions: Patient sitting with hands on hips and thumbs pointing posteriorly. Examiner places hand on top of affected shoulder and other hand on point of elbow. Examiner then applies a forward and superior force on the elbow. Patient asked to resist this force. Pain over the front of the shoulder or a click is positive.
- Apley' s Scratch test: abduction and external rotation are measured by having the patient reach behind the head and touch the superior aspect of the opposite scapula.
- Apprehension Test: is generally used to test the integrity of the glenohumeral joint capsule, or to assess glenohumeral instability in an anterior direction.
- Brachial Plexus Stretch Test – cervical facet joint impingement
- Biceps Load Test – superior glenoid labrum pathology

- Clunk Test: Patient supine, examiner hands on the posterior aspect of the shoulder, other hand holds the humerus above the elbow and abducts the arm over the head. Then pushing anteriorly with the hand under the shoulder and rotating the humerus laterally with the other hand, feel for a grind or clunk which may indicate a tear of the labrum.
- Crank Test: Patient is upright with the arm elevated to 160° in the scapular plane. Joint load is applied along the axis of the humerus with one hand while the other hand performs humeral rotation. The test can be repeated in supine. A positive test is indicated during the maneuver (usually during external rotation) if there is reproduction of symptoms with or without a click.
- Crossover Impingement Test – AC joint or rotator cuff pathology
- Drop Arm Test – rotator cuff pathology
- Feagin Test: arm abducted to 90º elbow straight arm on examiner's shoulder, a down and forward pressure is applied. Positive if apprehension and presence of anteroinferior instability.
- French horn Test: The patient is seated or standing. The examiner places the patient's arm to 90oin the scapular plane and flexes the elbow to 90º. The patient is then asked to externally rotate against resistance. The test is positive if the patient is unable to perform external rotation.
- Full Can Test: The patient can be seated or standing for this test. The patient's arm should be elevated to 90 degrees in the scapular plane, with the elbow extended, full internal rotation, and pronation of the forearm. This results in a thumbs-down position, as if the patient were pouring liquid out of a can.
- Gerber's Lift Off Test: The ability to actively lift the dorsum of the hand off the back constitutes a normal lift off test. Inability to move the dorsum off the back constitutes an abnormal lift off test and indicates subscapularis rupture or dysfunction.
- Grind Test: The patient standing and examiner standing facing the patient, the examiner grasps the patient's flexed elbow. The shoulder is passively abducted in the scapular plane to 90° (Hawkins-Kennedy test position). The examiner's other hand is placed over the patient's shoulder overlying the anterior acromion and greater tuberosity. The examiner passively internally and externally rotates the shoulder detecting the presence of palpable crepitus. The test was considered positive if resulted in palpable crepitus.
- Hawkins Test / Hawkins-Kennedy Impingement Test: The examiner places the patient's arm shoulder in 90º of shoulder flexion with the elbow flexed to 90º and then internally rotates the arm. The test is considered to be positive if the patient experiences pain with internal rotation.

- Hyper Extension-Internal Rotation (HERI) Test – anterior instability
- Jobe Relocation Test: The examiner repeats the apprehension test and notes the amount of external rotation before the onset of apprehension. They then return to the start position and apply a posterior stress over the humeral head. They then repeat the external rotation manoeuvre and again note the amount of external rotation at onset of apprehension.
- Load and Shift Test: anterior and posterior instability, the patient should be seated. The therapist stabilizes the scapula to the thorax with one hand, while the other hand is placed across the posterior GH joint line and humeral head, and the web space across the patient's acromion. The index finger should be over the anterior GH joint line. The clinician should now apply a "load and shift" of the humeral head across the stabilized scapula in an anteromedial direction to assess anterior stability, and in a posterolateral direction to assess posterior instability. Normal motion anteriorly is half of the distance of the humeral head, more movement is considered to be a sign of GH joint laxity.
- Ludington's Sign – long head of biceps pathology: The patient is instructed to clasp both hands on the top of their head. The examiner then palpates the biceps tendon and instructs the patient to alternate contraction and relaxation of the biceps muscle. A positive test is indicated by feeling the biceps tendon contract on the uninvolved side and an absence of contraction on the involved side.
- Neer Impingement Test: The examiner should stabilize the patient's scapula with one hand, while passively flexing the arm while it is internally rotated. If the patient reports pain in this position, then the result of the test is considered to be positive.
- O'Brien's Test – glenoid labrum / a-c joint pathology, with the patient in sitting or standing, the upper extremity to be tested is placed in 90° of shoulder flexion and 10-15° of horizontal adduction, the patient then fully internally rotates the shoulder and pronates the elbow, the examiner provides a distal stabilizing force as the patient is instructed to apply an upward force, the procedure is then repeated in a neutral shoulder and forearm position, a positive test occurs with pain reproduction or clicking in the shoulder with the first position and reduced/absent with the second position, depth of symptoms must also be assessed as superficial pain can indicate acromioclavicular joint symptoms and deep pain is more often a sign of a labral lesion
- Painful Arc Test – impingement of the supraspinatus tendon and/or subacromial bursa beneath the acromion
- Pectoralis Major muscle Contracture

- Piano Key Sign / Test: Subjects sit with the involved limb relaxed at the side, or stands facing the examiner. Action: Apply pressure to the subject's distal clavicle in an inferior direction. + Instability of the AC joint on the involved side.

- Posterior Drawer Test: (posterior instability) is performed by holding the patient's wrist or forearm with one hand and placing the other hand over the patient's shoulder so that the thumb is in the front and the fingers in the back. The thumb should be placed over the humeral head while applying a posteriorly directed force.

- Roos Test (thoracic outlet syndrome): The patient has both arms in the 90° abduction-external rotation position, shoulders and elbows are in the frontal plane of the chest, the patient is to open and close the hands slowly over a 3-minute period.

- Scarf Test (Cross Arm Adduction Test): is accomplished by reaching the hand over the opposite shoulder towards the scapula. This will aggravate AC joint arthritis, causing localised pain. With shoulder stiffness, external rotation is again the key movement lost. As already explained, this is commonly due to capsulitis.

- Shoulder Abduction Test: cervical facet joint impingement, the examiner should stand behind the patient on the side being tested. Grasp the patient's arm just distal to the elbow and passively flex the patient's shoulder to 90º. Then maximally adduct the patient's shoulder (bring it across their body towards the other shoulder).

- Speed's Test / Speed's Maneuver: Long head of biceps pathology, the examiner places the patient's arm in shoulder flexion, external rotation, full elbow extension, and forearm supination; manual resistance is then applied by the examiner in a downward direction.

- Sternoclavicular (SC) Joint Stress Test: Patient stands with involved arm relaxed at the side. The examiner stands in front of the subject placing one hand on the proximal end of the subject's clavicle and the other hand on the spine of the scapula. Apply gentle inferior and posterior pressure on the clavicle. Pain and/or movement of the clavicle indicates a sternoclavicular ligament sprain.

- Sulcus Sign: inferior instability, the test is considered positive when a sulcus sign is seen when the examiner applies a downward force applied at the elbow while the arm in neutral rotation and resting at the patient's side. A sulcus is defined as a depression greater than a fingerbreadth between the lateral acromion and the head of the humerus.

- Yergason's Test: is used to test for biceps tendon pathology or glenoid labrum, the patient should be seated or standing in the anatomical position, with the humerus in a neutral position and

the elbow in 90º of flexion in a pronated position. The patient is asked to externally rotate and supinate their arm against the manual resistance of the orthopaedic produced by wrapping the hand around the distal forearm (just above the wrist joint). Yergason's Test is considered positive if the pain is reproduced in the bicipital groove and a biceps or a SLAP lesion is suspected. If a "clicking" sensation familiar to the patient is produced during the test, damage to the transverse humeral ligament (which overlies the intertubercular sulcus) should be suspected too.

- Yocum's Test: is used to examine the shoulder rotator cuff impingement. Ask the patient to place the affected hand on the opposite shoulder, examiner elevates the elbow, if patient experience pain test indicates positive.

2.3.2. Elbow

The elbow joint is made up of three bones: the humerus of the upper arm and the radius and ulna of the lower arm (forearm). It is a synovial hinge joint. The movements of the joint are flexion, extension, pronation and supination. The elbow is one of the most commonly dislocated joints in the body. The following is a list of some of the many special tests that have been developed for the elbow.

2.3.2.1. Introduction

- Introduce yourself to the patient
- Wash your hands
- Briefly explain to the patient what the examination involves
- Ask the patients to place their hands on a pillow

Always start with inspection and proceed as below unless instructed otherwise; be prepared to be instructed to move on quickly to certain sections by the examiner.

- Palpation of elbow (See figure No. 10, 11)

Figure No. 10, 11 Palpation of lateral and medial epicondyles

2.3.2.2. Range of motion of the elbow: Flexion to 160 degrees, extension to 0 degrees, pronation (rotation inward) to 90 degrees, supination (rotation outward) to 90 degrees

2.3.2.3. Orthopaedic Special Tests for the Elbow:

- Cozen's Test (Lateral Epicondylitis): is a physical examination performed to evaluate for lateral epicondylitis or tennis elbow. The test is said to be positive if a resisted wrist extension triggers pain to the lateral aspect of the elbow owing to stress placed upon the tendon of the extensor carpi radialis brevis muscle. The test is performed with extended elbow. NOTE: With elbow flexed the extensor carpi radialis longus is in a shortened position as its origin is the lateral supracondylar ridge of the humerus. To rule out the ECRB (extensor carpi radialis brevis), repeat the test with the elbow in full extension.
- Golfer's Elbow Test (Medial Epicondylitis): The patient should be seated or standing and should have his/her fingers flexed in a fist position. The examiner palpates the medial epicondyle with one hand and grasps the patient's wrist with his/her other hand. The examiner then passively supinates the forearm and extends the elbow and wrist.
- Mill's Test: Palpate the lateral epicondyle while passively pronating the forearm, flexing the wrist and extending the elbow. A positive test is reproduction of lateral elbow pain.
- Pinch Grip Test: the fingers are on one side of an object, and the thumb is on the other. Typically, an object lifted in a pinch grip does not touch the palm.
- Tinel's Sign: The Tinel's sign test is often used to help diagnose carpal tunnel syndrome, cubital tunnel syndrome, or tarsal tunnel syndrome. A positive result means you feel a tingling sensation when your doctor taps the affected nerve.
- Valgus Stress Test: A positive test occurs when pain or excessive gapping occurs (some gapping is normal at 30º).
- Varus Stress Test: A positive test occurs when pain or excessive gapping occurs (some gapping is normal at 30º).

2.3.3. Wrist and Hand

2.3.3.1. Introduction

- Introduce yourself to the patient
- Wash your hands
- Briefly explain to the patient what the examination involves
- Ask the patients to place their hands on a pillow

Always start with inspection and proceed as below unless instructed otherwise; be prepared to be instructed to move on quickly to certain sections by the examiner.

2.3.3.2. Inspection

Ask the patient to pronate their hands

- Inspect for pathology in the:
- Nails
- Heberden's (DIPJ) or Bouchard's (PIPJ) nodes (present in osteoarthritis)
- Dorsum of the hand
- Check the rotational axis of each finger (look from the tips of the fingers) to assess for any rotational deformity

Ask the patient to supinate their hands

- Assess for any obvious pathology in the palms (e.g. Dupuytren's contractures)

Ask the patient to flex their elbows and show you their elbows / dorsal surface of their forearms

- Check for psoriatic plaques, rheumatoid nodules, or gouty tophi
- Number of fingers polydactyly or syndactyly (See figure No. 12, 13).

Figure No. 12, 13 Polydactyly

2.3.3.3. Palpation

Ask the patient to again place their hands back on the pillow, in a supine position:

- Assess temperature
- Using the dorsal surface of your own hand, feel distal to proximal along the patient's hand and forearm, and compare with the contralateral side
- Feel for the radial pulse
- Assess the muscle bulk of the thenar eminence and hypothenar eminence
- Run the pad of your thumb firmly over these areas
- Compare for asymmetry, caused commonly by disuse or denervation (i.e. carpal tunnel syndrome)
- Assess the tendons of the hand, feeling for nodules or contractures
- Assess again by running down with the pad of your thumb

Ask the patient to pronate their hands:

- Palpate the bony anatomy of the hands, feeling for any tenderness
- The radial and ulnar styloid processes
- The carpal bones
- Along the length of each metacarpal
- Gently squeeze all 4 MCP joints together (often painful in inflammatory arthropathies)

- Bimanually palpate all of the MCP joints, PIP joints, and DIP joints
- This is best done by placing the thumb and index finger around the joint in a pincer-like grip, and the other hand the same at 90o to the first hand, feeling for tenderness and laxity in the joint.

2.3.3.4. Movement

Ask the patient to keep the hands in the pronated position:

- Check the extensors of the hand, asking the patient to
- Extend the wrist against resistance (extensors)
- Raise the thumb off of the pillow (EPL)
- Hold the wrist passively in extension and ask the patient to extend their fingers (ED)
- Flex the fingers to 90o at the MCP joints and ask the patient to extend their fingers again (lumbricals)

Ask the patient to supinate the hands:

- Check the flexors of the hand, asking the patient to
- Flex the wrist against resistance
- Flex the fingers at the PIP joints
- Isolate the 3 fingers that are not being tested (simply hold them in the natural anatomical position) and ask the patient to flex the finger being tested (FDS)
- Flex the fingers at the DIP joints
- Isolate the proximal and middle phalanges by holding them firmly and then asking the patient to flex the distal phalanx of that finger (FDP)
- Check the action of the wrists, asking the patient
- Abduct their wrists against resistance
- Adduct their wrists against resistance

Normal values for wrist ROM are 73º of flexion, 71º of extension, 19º of radial deviation, 33º of ulnar deviation, 140º of supination, and 60º of pronation (See figures No. 14, 15, 16, 17).



Figure 14 Ulnar deviation of wrist

Figure 15 Radial deviation of wrist

Figure No. 16 Flection of wrist

Figure No. 17 Extention of wrist

Check the action of the thumbs, asking the patient to

• Flex the thumb (FPL)

• Abduction the thumb (APL and APB)

• Adduction the thumb (AP)

• Opposition the thumb (OP)

Assess the functioning of the hand by assessing:

• Power grip

• Place two fingers in to the patient's palm and ask them to squeeze as firmly as possible

• Pincer grip

• Ask the patient to pinch the tip of your finger

• Fine motor function

• Ask the patient to pick up a penny or do up the buttons on a shirt

Check the sensorimotor function of the terminal branches of the brachial plexus:

• Median nerve

• Motor – confirm thumb abduction is present (tests APB)

• Sensation – check at the radial border of tip of index finger

• Radial nerve

• Motor – confirm MCPJ extension is present (tests ED)

• Sensation – check at the dorsal surface of first digital web space

• Ulnar nerve

• Motor – confirm finger abduction & adduction (tests palmar and dorsal interossei)

• Sensation – check at the ulnar border of tip of little finger

Assess the vascular status of the hand by assessing:

• Colour / temperature / capillary refill time

2.3.3.5. Special Tests

• **Phalen's Test** (test for carpal tunnel syndrome)

Ask the patient to place the dorsal surfaces of their hands together and then fully flex the wrists (the 'reverse prayer'). Hold for 30–60 seconds. This will reproduce their symptoms in positive cases

• **Tinel's Test** (test for carpal tunnel syndrome)

Gently percuss over the volar aspect of the carpal tunnel – this is found just distal to the wrist crease, overlying the carpal bones. In a positive test, the patient will report paraesthesia in the distribution of the median nerve

• **Finkelstein's Test** (test for DeQuervain's Tenosynovitis)

The thumb is flexed across the palm and the fingers are then wrapped around it. The wrist is then passively adducted (or ulnar deviated). This causes a disproportionate amount of pain over the radial styloid on the affected side.

Lower limb examinations

2.3.4. Hip

The hip joint is a ball and socket joint and is the joint in the body with the greatest range of motion other than the shoulder. It is surrounded by very strong ligaments and muscles, making it a very stable joint. The hip is a very stable joint because it has to handle a great deal of force and still have such a large range of motion. The following is a list of some of the many special tests that have been developed for the hip.

2.3.4.1. Introduction

- Introduce yourself to the patient
- Wash your hands
- Briefly explain to the patient what the examination involves
- Ask the patient to remove their bottom clothing, exposing the hip
- Offer the patient a chaperone, as necessary

Always start with inspection and proceed as below unless instructed otherwise; be prepared to be instructed to move on quickly to certain sections by the examiner.

2.3.4.2. Inspection

Whilst the patient is standing:

- Assess patient gait, such as limbing
- Trendelenburg gait – caused by dysfunction of the hip abductors (gluteus medius and minimus), the patients contralateral hip drops when walking; the patient often offsets this by leaning their trunk toward the affected hip
- Antalgic – produced from weight bearing on painful leg, resulting in a shortened stance-phase and producing the characteristic 'limping' patient
- Examine for quadriceps muscle bulk

Ask the patient to lie supine on the bed:

- Assess for:
- Skin changes (uncommon in primary hip pathology as the joint is deep)
- Scars (indicative of previous surgery)
- Swelling (also uncommon, as the joint is deep)
- Measure leg length with a tape measure. This assesses whether there is an actual leg length

discrepancy and whether there is any pelvic tilt present to compensate for this:

- True leg length = ASIS to medial malleolus

- Apparent leg length = pubic symphysis to medial malleolus

2.3.4.3. Palpate

- Assess for temperature
- Feel for trochanteric bursa tenderness
- Palpate over the greater trochanter

2.3.4.4. Movement

All movements are passive when examining the hip, ensuring to note any pain, the range of motion, and any crepitus.

- Abduction 30 to 50º and adduction 20 to 30º
- Place one hand across the patient's pelvis to ensure that the pelvis remains still and that the movement is coming from the hip joint and not the pelvis
- Flexion and extension 110 to 125º
- Internal up to 64º and external rotation up to 45º (assessed with the hip flexed) (vary by age) (See figures No. 18, 19).

Figure No. 18 External rotation of hip

Figure No. 19 Internal rotation of hip

2.2.4.5. Orthopaedic Special Tests for the Hip

- **Thomas' Test** (assesses for fixed flexion deformity): Have the patient lying in the supine position, and place one hand underneath the patient's lumbar spine to ensure loss of the lumbar lordosis. Fully flex the contralateral hip and observe the ipsilateral hip (i.e. the one that you are examining). Any flexion in this hip suggests a fixed flexion deformity. Repeat this test on both sides
- **Trendelenburg test** (assesses abductor muscle function): Ask patients to place their hands on your outstretched hands (for stability) and ask them to stand on the leg that you are examining, lifting the contralateral leg off the ground (for 30 seconds).
- Feel for a drop in the pelvis on the contralateral side. If there is abductor pathology (gluteus medius and minimus) on the side you are examining then the contralateral side (the normal side) will sag down ("Sound Side Sags")
- **Ely's Test**: Patient prone; flex the affected knee toward the buttocks; make sure leg does not abduct; observe the pelvis, if pelvis on affected side flexes as the knee is being flexed, indicates short rectus femoris.
- **Gaenslen's Test**: is one of the five provocation tests that can be used to detect musculoskeletal abnormalities and primary-chronic inflammation of the lumbar vertebrae and Sacroiliac joint (SIJ). The subsequent tests include; the Distraction Test, Thigh Thrust Test, Compression Test and the Sacral Thrust Test.
- **Hibb's Test**: Used to compare degrees of movement at sacroiliac joints. Prone patient flexes knee to 90¡, and examiner rotates hip on side to be tested as far medially as possible and simultaneously palpates sacroiliac joint. Maneuver is then performed on the other side and findings compared.

- **Nachlas Test:** The examiner flexes the patient's knee to a right angle; then, with pressure against the anterior surface of the ankle, the heel is slowly directed straight toward the ipsilateral buttock. The contralateral ilium should be stabilized by the examiner's other hand.
- **Ober's Test**: is used in physical examination to identify tightness of the iliotibial band (iliotibial band syndrome). During the test, the patient lies on his/her side with the unaffected leg on the bottom with their shoulder and pelvis in line.
- **Patrick's Test**: is performed to evaluate pathology of the hip joint or the sacroiliac joint. The test is performed by having the tested leg flexed and the thigh abducted and externally rotated.
- **Pelvic Rock Test**: Passive, lie on side with involved side up. Apply downward pressure on the ilium, test for iliac compression, (+) pain at SI = inflammation of SI joint, or ilium fracture.
- **Telescoping Sign**: The telescoping test is used to check for hip dislocations. To perform the test the patient lies down flat on their back. The examiner then raises one of the patient's legs up so that the knee is bent at a 90 degree angle. Then, with one hand on the patient's knee, and the other grasping the patient's upper calf, the physical therapist raises the patient's knee upward, then back down. The physical therapist is looking for laxity of the hip joint.
- **Yeoman's Test**: is a physical exam performed to determine if a person has sacroiliitis, sacroiliac joint sprain or strain. With the subject prone, the test is performed by rotating the ilium with one hand and extending the hip while the knee is flexed. Pain over the ipsilateral posterior sacroiliac joint area is indicative of sacroiliitis.

2.3.4.6. Special tests for newborn (infant) to roll out Developmental dysplasia of hips (DDH)

- **Ortolani test:** is performed by an examiner first flexing the hips and knees of a supine infant to 90°, then with the examiner's index fingers placing anterior pressure on the greater trochanters, gently and smoothly abducting the infant's legs using the examiner's thumbs. Click in test.
- **Barlow test:** The manoeuvre is easily performed by adducting the hip (bringing the thigh towards the midline) while applying pressure on the knee, directing the force posteriorly. Click out test.
- **Galeazzi test:** It is performed by flexing an infant's knees when they are lying down so that the feet touch the surface and the ankles touch the buttocks (See figure No. 20).

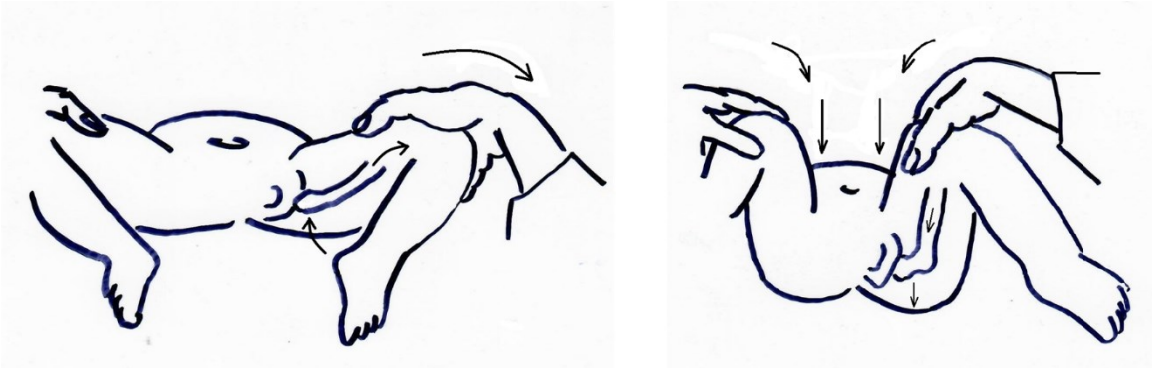

Figure No. 20 Ortolani test and Barlow test.

2.3.5. Knee

The knee is the largest joint in the body and is also the most commonly injured joint. As a result there are many special tests that have been developed to help diagnose the source of knee pain, stability and function. The following is a list of some of the many special tests that have been developed for the knee.

2.3.5.1. Introduction

- Introduce yourself to the patient
- Wash your hands
- Briefly explain to the patient what the examination involves
- Ask the patient to remove their bottom clothing, exposing the entire knee
    - Offer the patient a chaperone, as necessary

Always start with inspection and proceed as below unless instructed otherwise; be prepared to be instructed to move on quickly to certain sections by the examiner.

2.3.5.2. Inspection

Whilst the patient is standing:

- Assess patient gait. Common gaits include:
- Antalgic: produced from weight bearing on painful leg. The stance-phase is shortened, producing the characteristic 'limping' patient.
- Trendelenburg: weakness of the hip abductors (gluteus medius + minimus). This is general examination finding, rather than a sign of knee pathology.
- Assess symmetry and for deformity
- Level of patellae bilaterally
- Genu varum (or bowlegged), where the tibia is angulated medially in relation to the femur
- Genu valgum (or knock-kneed), where the tibia is angulated laterally in relation to the femur
- Assess quadriceps muscle bulk
- These waste rapidly (within weeks) in knee disease

Figure No. 21 Right knee effusion

Ask the patient to lie supine on the bed

Assess for:

- Skin changes (e.g. erythema from septic arthritis)
- Scars (e.g. previous arthroplasty or arthroscopy)
- Swellings, including joint effusions, inflamed bursa (typically prepatellar and infra-patella bursae), parameniscal cysts, or Baker's cysts (See figure No. 20)
- Leg axis (See figure No. 21)

Figure No 22 Leg deformation

2.3.5.3. Palpate

- Assess temperature, comparing both sides
- Start at the mid-thigh and work to the mid-shin

- Palpate the extensor mechanism:
- Start with quadriceps muscle and quadriceps tendon, feel around the patella and the patellar ligament, and then press over the tibial tuberosity
- Check for a joint effusion

2.3.5.4. Assessing for Joint Effusion

Two methods can be used to assess for joint effusion in the knee:

- The Sweep Test – Milk the suprapatellar pouch, keeping the hand firmly pressed on the distal thigh, to ensure all fluid is pushed and retained within the knee joint. Use the other hand to concurrently 'sweep' away fluid from the medial gutter. With the initial hand still in place, 'sweep' the lateral gutter from distal to proximal, and whilst doing this, look closely at the medial gutter – if you see a bulge, this indicates a small joint effusion
- The Patella Tap Test – As above, empty the suprapatellar pouch, and with the other hand, press firmly down the patient's patella. You will feel its undersurface 'tapping' against the trochlea of the distal femur. This is a crude test for a large joint effusion, although these can also be apparent on inspection.

Palpate the origin and insertion of the MCL and LCL

- Palpate the menisci
- Flex the knee to 90 degrees and palpate across the medial and lateral joint lines
- Palpate the popliteal fossa:
- With the knee still flexed, palpate for masses posterior to the knee, such as Baker's cysts or popliteal aneurysms.

2.3.5.5. Movement

- Straight leg raise
- Place your hand around 30 cm off the bed and ask the patient to kick it, keeping their leg straight, demonstrating the integrity of the extensor mechanism
- Check for hyperextension (most knees extend to 5º beyond neutral) (See figure No. 22)
- Place your fist under the patients heel and ask them to push their knee in to the couch
- Check range of flexion 135°
- place your hand over their anterior knee and ask them to flex as far as they can, also noting any crepitus.

Figure No 23 Knee hyperextension

2.3.5.6. Special Tests

Assess the stability of the knee ligaments:

Assess the ACL:

- **Lachmann's Test:** Flex the knee to 30º. Place one hand on the distal femur and one hand on the proximal tibia. Firmly pull the tibia anteriorly, whilst stabilising the femur with the contralateral hand. Feeling for laxity (that is greater than the contralateral side) and absence of a solid end point
- **Anterior drawer test:** Flex the knee to 90º and sit on the patient's foot. With both hands, grasp the proximal tibia at the level of the tuberosity. Pull firmly anteriorly, also assessing for laxity and end point (See figure No. 24).
- **Assess the PCL: Posterior drawer test:** Flex the knee to 90º and sit on the patient's foot. With both hands, grasp the proximal tibia at the level of the tuberosity. Push firmly posteriorly, assessing for laxity and end point (See figure No. 23).

Figure No. 24 Anterior drawer test of the knee

Figure No. 25 Posterior drawer test of the knee

Assess the MCL and LCL, using the stress tests: Flex the knee to 30º and hold the ankle between your arm and torso. Place hands on opposing sides of the knee and firmly push the knee in to valgus stress and varus stress. Note pain and laxity with this manoeuvre (See figure No. 24, 25).

Figure No. 26 Stress test of lateral collateral ligament of knee

Figure No. 27 Stress test of medial collateral ligament of knee

- **Bounce Home Test:** Patient supine with knee flexed & heel cupped in therapist hand; knee is passively allowed to extend. Findings: Incomplete extension or springy block end feel indicates that likely a torn meniscus is blocking movement.
- **Apley's Compression/Grinding Test:** Patient lies prone on examining table, testing leg flexed to 90 degrees, Compression test lean on patient's foot, applying pressure to heel compresses tibia into femur, rotate tibia internally and externally on femur.
- **Apprehension Sign:** This is a sound test to find out whether a patient is having symptoms for a subluxing or dislocating patella. The examiner then slowly applies an external rotation force to the arm to 90º while carefully monitoring the patient. Patient apprehension from this manoeuvre, not pain, is considered a positive test.
- **McMurray's Test:** is performed with the patient supine and relaxed. The examiner grasps the patient's heel with one hand and the joint line of the knee with the other hand. The knee is flexed maximally, with external tibial rotation (medial meniscus) or internal tibial rotation (lateral meniscus).
- **Noble Compression Test:** is a provocative test of the iliotibial band, developed by Clive Noble. It is commonly used as an indication for iliotibial band syndrome; however, no evidence-based research has been done yet to control the validity of this test.
- **Patellar Grind Test:** Place one hand superior to the patella and push the patella inferiorly. Ask the patient to tighten the quadriceps muscle against this patellar resistance. A grinding sound and/or pain may indicate patellofemoral chondromalacia. However, this test is often positive for grinding and/or pain in patients with normal knees.
- **Pivot Shift Test:** is performed with the patient lying in the supine position with the hip passively flexed to 30º and it is important to abduct the hip to relax the iliotibial tract

and allow the tibia to rotate. The examiner stands lateral to the patient on the side of the knee that is being examined. The lower leg and ankle is grasped maintaining 20º of internal tibial rotation. The knee is allowed to sag into complete extension. The opposite hand grasps the lateral portion of the leg at the level of the superior tibiofibular joint, increasing the force of internal rotation. While maintaining internal rotation, a valgus force is applied to the knee while it is slowly flexed. If the tibia's position on the femur reduces as the knee is flexed in the range of 30 to 40 degrees or if there is an anterior subluxation felt during extension the test is positive for instability.

- **Posterior Drawer Test** – ligamentous stability
- **Posterior Tibial Sag:** Have the patient lie supine on the exam table.

The examiner raises the leg until the hip and knee are at 90° of flexion. Support the leg under the lower calf or heel in the air. Patient's leg should be relaxed. Observe the position of the tibia in comparison to the femur.

- **Slocum's Test:** The patient is lying supine with the knee flexed 90º and the foot fixed to the examining table by the examiner. 30º of internal rotation is applied to the tibia by rotating the foot. The examiner pulls anteriorly on the tibia to assess for anterolateral rotary instability. Results are compared bilaterally.

Positive: Increased amount of anterior tibial translation with tibial internal rotation or excessive movement on the lateral aspect of the knee indicates anterolateral instability.

- **Thessaly Test** – meniscal tear / lesion: the patient stands on the test leg with the knee bent to 20º of flexion (the opposite leg is flexed behind the patient). The patient may place his/her hands on the hands of the examiner for balance during the test. The patient then rotates the knee medially and laterally 3 times each direction. A positive test occurs when the patient experiences joint line discomfort or if locking/catching occurs.
- **Valgus Stress Test** – ligamentous stability
- **Varus Stress Test** – ligamentous stability

2.3.6. Ankle

The ankle consists of three joints; talocrural joint, the subtalar joint, and the Inferior tibiofibular joint. The talocrural joint is commonly known as the ankle proper and is a synovial hinge joint. The ankle consists of three bones; the talus, the fibula and the tibia.

2.3.6.1. Introduction

- Introduce yourself to the patient
- Wash your hands
- Briefly explain to the patient what the examination involves
- Ask the patient to remove their bottom clothing, exposing the entire the ankle and foot
- Offer the patient a chaperone, as necessary

Always start with inspection and proceed as below unless instructed otherwise; be prepared to be instructed to move on quickly to certain sections by the examiner.

2.3.6.2. Inspection

Whilst the patient is standing:

- Assess patient gait. Common gaits include:
- Antalgic: produced from weight bearing on painful leg. The stance-phase is shortened, producing the characteristic 'limping' patient.
- Trendelenburg: weakness of the hip abductors (gluteus medius + minimus). This is general examination finding, rather than a sign of ankle pathology.
- Assess symmetry and for deformity

2.3.6.3. Palpate

- Assess temperature, comparing both sides
- Palpate the extensor mechanism
- Check for a joint effusion

2.3.6.4. Movement

The movements of the joint are dorsal flexion up to 30° and plantar flexion up to 50°.

Eversion and inversion in the ankle joint (See figure No. 26, 27).

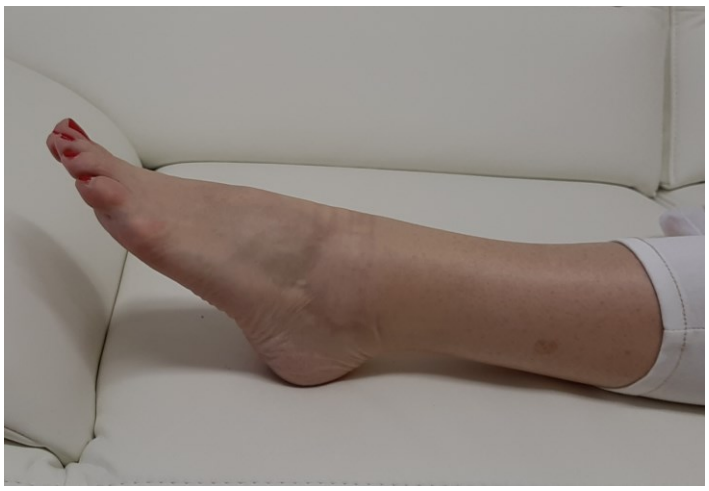

Figure No.28 Ankle plantar flexion

Figure No.29 Ankle dorsal flexion

2.3.6.5. Orthopaedic Special Tests for the Ankle

- Anterior Drawer Test: assesses the stability of the anterior talofibular ligament. With the patient seated and the knee flexed approximately 90°, place the ankle in approximately 20° of plantar flexion. When performing this test, always compare the affected ankle with the opposite (normal) side.
- **Compression Test:** assesses the stability
- **Eversion Stress Test:** assesses the stability
- **Eversion Talar Tilt Test:** assesses the stability

- **Feiss' Line Test:** A line from the medial malleolus to the plantar aspect of the first metatarsophalangeal joint, used to measure pronation of the foot during weight bearing.

- **Heel Tap Test:** Markle Test or Heel Drop Jarring Test is elicited in patients with intraperitoneal inflammation by having a patient stand on his or her toes and suddenly dropping down onto the heels with an audible thump. If abdominal pain is localised as the heels strike the ground, Markle Sign is positive.

- **Homan's Sign Test:** also called dorsiflexion sign test is a physical examination procedure that is used to test for Deep Vein Thrombosis (DVT). A positive Homan's sign in the presence of other clinical signs may be a quick indicator of DVT.

- **Inversion Stress Test:** The inversion stress test evaluates laxity of the calcaneofibular ligament. With the patient seated and the knee flexed approximately 90°, use one hand to stabilize the medial aspect of the leg just above the medial malleolus. Place your other hand somewhat inferolateral on the calcaneus (A) and invert the hindfoot (B). An end point should normally be appreciated upon reaching full inversion, and absence of one indicates moderate to severe injury to the calcaneofibular ligament. Excessive or asymmetric motion will occur with chronic laxity of the calcaneofibular ligament. When performing this test, always compare the affected ankle with the opposite side. If the patient has pain during this test, the results may be unreliable.

- **Inversion Talar Tilt Test:** or inversion stress manoeuvre is performed with the patient supine or on his/her side, with the foot relaxed. The gastrocnemius must also be relaxed by flexion of the knee. The talus is then tilted from side to side into adduction and abduction.

- **Kleiger's Test (External Rotation Test):** also known as the external rotation test, determines the rotary damage to the deltoid ligament or the distal tibiofibular syndesmosis which is injured in a high ankle sprain. The tests place lateral force on the tibia, spreading the syndesmosis and stretching the deltoid ligament.

- **Thompson's Squeeze Test – for Achilles tendon rupture:** The Thompson test examines the integrity of the Achilles tendon by squeezing the calf.

- **Tibial Torsion Test:** is assessed by measuring the thigh-foot angle, if the foot is shaped normally. While the child is relaxed and lying on his stomach, with his knee and ankle each at 90º, imagine a line from the second toe to the middle of his heel.

2.3.7. Foot

2.3.7.1. Introduction

- Introduce yourself to the patient
- Wash your hands
- Briefly explain to the patient what the examination involves
- Ask the patient to remove their shoes and socks, exposing the entire the foot
- Offer the patient a chaperone, as necessary

Always start with inspection and proceed as below unless instructed otherwise; be prepared to be instructed to move on quickly to certain sections by the examiner.

2.3.7.2. Inspection

Whilst the patient is standing:

- Assess patient gait. Common gaits include:
- Antalgic: produced from weight bearing on painful leg. The stance-phase is shortened, producing the characteristic 'limping' patient.
- Trendelenburg: weakness of the hip abductors (gluteus medius + minimus). This is general examination finding, rather than a sign of ankle pathology.
- Assess symmetry and for deformity

2.3.7.3. Palpate

- Assess temperature, comparing both sides
- Palpate the extensor and flexor mechanism
- Check for a joint effusion

2.3.7.4. Movement

The triplanar movements of the foot are: transverse plane adduction/abduction, frontal plane inversion/eversion, and sagittal plane dorsiflexion/plantar flexion. These movements can further compound into the positions of supination up to 5°.

2.3.7.5. Podoscopic (foot print) test

To Analyse and determinate the arches of both feet longitudinal and transverse arches and to roll out flatfoot (See figure No. 28, 29).

Figure No. 30, 31 Podoscopic Machine

2.4. Complete the Examination

Thank the patient once completed. Remember, if you have forgotten something important, you can go back and complete this. State to the examiner that to complete your examination you would also like to examine the joint above or below, the contralateral hand, and review any relevant imaging available.

2.5. Orthopaedic Diagnostic Tests

Orthopaedic surgeons use a variety of diagnostic tests to help identify the specific nature of your musculoskeletal injury or condition. Orthopaedists also use results of these tests to plan an appropriate course of treatment. Here are some of the most frequently used diagnostic tests for musculoskeletal injuries and conditions.

2.5.1. Laboratory Studies

Laboratory studies of blood, urine or joint (synovial) fluids are used to identify the presence and amount of chemicals, proteins, and other substances. Your doctor may order various laboratory studies depending on what he or she finds during the initial examination. For example, laboratory studies can identify the amount of uric acid in the blood, which is an indicator of gout. A high white blood cell count in joint fluid may indicate severe inflammation or infection. Laboratory tests (see figure No.30, 31) are usually required before surgeries to identify medical abnormalities.

Figure No.32, 33 Venepuncture for blood tests

You may be required to fast for a specific number of hours before donating samples for a laboratory test.

1. **Complete blood cell count (CBC) and deferential**
2. **Laboratory Blood tests for infections:**

- **C-reactive protein (CRP):** is a blood test marker for inflammation in the body.
- **The erythrocyte sedimentation rate (ESR)**
- **Blood culture:** is a test that checks for foreign invaders like bacteria, yeast, and other microorganisms in your blood.

- **Procalcitonin (PCT):** a protein that consists of 116 amino acids, is the peptide precursor of calcitonin, a hormone that is synthesized by the parafollicular C cells of the thyroid and involved in calcium homeostasis. Procalcitonin arises from endopeptidase-cleaved preprocalcitonin.
- **The rheumatoid arthritis (RA) latex turbid test:** is a laboratory test that's used to help to diagnose RA and other autoimmune diseases.
- **Antistreptolysin O (ASO or ASLO):** Is the antibody made against streptolysin O, an immunogenic, oxygen-labile streptococcal hemolytic exotoxin produced by most strains of group A and many strains of groups C and G Streptococcus bacteria. The "O" in the name stands for oxygen-labile; the other related toxin being oxygen-stable streptolysin-S. The main function of streptolysin O is to cause hemolysis (the breaking open of red blood cells) — in particular, beta-hemolysis.

  Increased levels of ASO titre in the blood could cause damage to the heart and joints in most cases.
- **Abscess or Joint fluid:** A culture of your joint fluid is a laboratory test. It identifies organisms that can cause infection in your joint fluid or abscess. The joint fluid or bus is also used to test for the presence of protein, glucose, or crystals.

3. **Minerals:**

- **Blood calcium** levels can be measured to find out whether someone is getting enough calcium, but this does not provide any information about how much calcium there is in their bones.
- **Magnesium (Mg):** deficiency worsens, symptoms may include: numbness, tingling, muscle cramps, seizures, muscle spasticity, personality changes, abnormal heart rhythms.
- **Phosphorus (P):** works together with the mineral calcium to build strong bones and teeth.

4. **Laboratory blood tests for osteoporosis**

- **Bone-specific alkaline phosphatase (Bone ALP or BALP):** This is an estimate of the rate of bone formation over your entire skeleton.
- **Urinary N-telopeptide of type I collagen, or uNTX.** This is a marker of bone resorption, or loss of bone.

- **Parathyroid Hormone (PTH):** To determine the cause of calcium imbalances; to evaluate parathyroid function; to diagnose and differentiate between primary, secondary, and tertiary hyperparathyroidism; to diagnose hypoparathyroidism; during surgery for hyperparathyroidism to confirm removal of the gland(s) causing the problem.
- **P1NP (total procollagen type 1 N-terminal propeptide):** is the preferred marker for bone formation.
- **CTX Collagen Type-1 C-telopeptide:** is a marker of bone resorption; an elevated blood level is a sign of accelerated resorption (and bone turnover), sometimes resulting from low estrogen. Bisphosphonate drugs, which are used to treat osteoporosis, block resorption and thus cause CTX levels to fall.
- **Osteocalcin:** is produced by osteoblasts, it is often used as a marker for the bone formation process. It has been observed that higher serum osteocalcin levels are relatively well correlated with increases in bone mineral density during treatment with anabolic bone formation drugs for osteoporosis, such as teriparatide.
- **Homocysteine:** Abnormally high levels of homocysteine in the serum, above 15 µmol/L, are a medical condition called hyperhomocysteinemia. This has been claimed to be a significant risk factor for the development of a wide range of diseases, including thrombosis, neuropsychiatric illness, and fractures. It also is found to be associated with microalbuminuria, which is a strong indicator of the risk of future cardiovascular disease and renal dysfunction. Vitamin B12 deficiency

5. **Vitamin D levels:** This measure assesses whether you have a deficiency of vitamin D, which is essential for your body's absorption of calcium.
6. **Uric Acid:** To detect high levels of uric acid in the blood, which could be a sign of the condition gout, or to monitor uric acid levels when undergoing chemotherapy or radiation treatment; to detect high levels of uric acid in the urine in order to diagnose the cause of kidney stones and to monitor those with gout who are at risk of developing such stones.
7. **Urine:**

- **Urinalysis:** is a group of physical, chemical, and microscopic tests. The tests detect and/or measure several substances in the urine, such as byproducts of normal and abnormal metabolism, cells, cellular fragments, and bacteria.
- **Urine culture and sensitivity:** Catheterized specimen urine culture is a laboratory test that looks for germs in a urine sample.

As part of your examination, your orthopaedist may order a variety of blood tests. Some conditions, such as rheumatoid arthritis, may be identified by the presence of a specific substance in your blood. You may be asked to fast prior to the exam. Usually a blood test is a simple matter that involves withdrawing a small amount of blood from your arm.

2.5.2. Radiography (X-ray)

X-rays (radiographs) are the most common and widely available diagnostic imaging technique. Even if you just complain about a sprain in your wrist or ankle, your doctor will probably order radiographs to make sure no bone is broken. X-rays are always used for fractures and joint dislocations, and may also be recommended if your doctor suspects damage to a bone or joint from other conditions such as arthritis or osteonecrosis (bone cell death). The part of your body being pictured is positioned between the X-ray machine and photographic film. As you hold still, the machine briefly sends electromagnetic waves (radiation) through your body. This exposes the film, creating a picture of your internal structure. The level of radiation exposure from X-rays is minimal, but your doctor will take special precautions if you are pregnant. Bones, tumours and other dense matter appear white or light because they absorb the radiation. Soft tissues and breaks in bone let radiation pass through, making these parts look darker. Sometimes, to make certain organs stand out in the picture, you are asked to drink barium sulphate or be injected with a dye. Several X-rays from different angles may be needed. If you have a fracture in one limb, your doctor may want a comparison X-ray of your uninjured limb. Your X-ray session will probably take 10 to 15 minutes; no specific preparations are required (See figure No. 32, 33, 34).

Figure No. 34, 35 X-Ray digital machine

Figure No. 36 X-Ray beam

The difference in body tissue density:

- Bone – with a high density – appears white on a radiograph
- Fat – with a low body tissue density – appears gray
- Air – with no density – appears black

2.5.2.1 Special views X-Ray

The basic views of radiographs are anteroposterior (AP) view and lateral view, there are so many views like:

- Oblique view
- The AP mortise view is done with the leg internally rotated 15-20º so that the x-ray beam is perpendicular to the inter-malleolar line.
- Inlet view, best demonstrates ring configuration of pelvis, narrowing or widening of diameter of ring is immediately apparent.
- Outlet or tangential view shows the anterior ring superimposed on the posterior ring.
- The open mouth odontoid radiograph is used to assess for the presence of an upper cervical spine injury.
- All spine views X-ray (See figure No. 35).

Figure No. 37 X-Ray of the spine (Scoliosis)

2.5.3. Bone Scan

Two very different kinds of tests may be called bone scans. One type tests the density of the bone and is used to diagnose osteoporosis. This type of bone scan uses narrow X-ray beams or ultrasound to see how solid the bone is. No preparation is required for this test, which takes only a few minutes and has no side effects. (See Dual-Photon Absorptiometry, Dual-Energy X-ray Absorptiometry, and Peripheral Bone Density Testing.)

The second type of bone scan is used to identify areas where there is unusually active bone formation. It is frequently used to pinpoint stress fracture sites or the presence of arthritis, infection, or cancer. About three hours before the scan, you will be given a dose of a mildly radioactive substance called "technetium" through an intravenous line. This substance occurs naturally in your body and is used in the bone formation process. The bone scan itself is performed about three hours later, which gives the bone time to absorb the technetium. As you lie on a table, a special nuclear camera takes a picture of your entire body. This process takes 30 to 90 minutes. Areas of abnormal bone formation activity will appear brighter than the rest of the skeleton.

No fasting or other preparation is required. The amount of radioactivity absorbed during a technetium bone scan is minimal, and there are usually no side effects. You may feel some discomfort as the IV line is placed. Some people may feel nauseous. Tell your physician if you are or may be pregnant or are a nursing mother before you schedule this test.

2.5.4. Computed Tomography (CT scan)

A CT scan (computed tomography) combines X-rays with computer technology to produce a more detailed, cross-sectional image of your body (See figure No 36). It may be ordered if your doctor suspects a tumour or a fracture that doesn't appear on X-rays (such as in your collarbone or pelvis) or if you've had severe trauma to the chest, abdomen, pelvis or spinal cord. The process is painless. You lie motionless on a table as it slides into the centre of the cylinder-like CT scanner. An X-ray tube slowly rotates around you, taking many pictures from all directions. A computer combines the images to produce a clear, two-dimensional view on a television screen. You may need to drink or be injected with barium sulfate or a dye so that certain parts of your body can be seen more clearly. The drink has a chalky taste and may make you feel nauseous; a dye injection may be moderately painful. Tell your doctor if you are pregnant before undergoing a CT scan.

Figure 38 CT machine

2.5.3.2 CT Angiography and CT Perfusion Imaging

Computed tomography angiography (also called CT angiography or CTA) is a computed tomography technique used to visualize arterial and venous vessels throughout the body. Using contrast injected into the blood vessels, images are created to look for blockages, aneurysms (dilations of walls), dissections (tearing of walls), and stenosis (narrowing of vessels). CTA can be used to visualize the vessels of the heart, the aorta and other large blood vessels, the lungs, the kidneys, the head and neck, and the arms and legs.

2.5.3.2.1. Technique:

CT angiography is a contrast CT where images are taken with a certain delay after injection of radiocontrast material. The contrast material is radio dense causing it to light up brightly within the blood vessels of interest. In order for the CT scanner to be able to scan the correct area where the contrast is, the scanner uses either automatic detectors which start scanning when enough contrast is present, or small test boluses. With the small test bolus a small amount of contrast is injected in order to detect the speed that the contrast will move through the blood vessels. After determining this speed, the full bolus is injected and the scan is begun at the timing determined by the test bolus. After the scan is completed the images are post-processed to better visualize the vessels and can even be created in the 3D images.

2.5.3.3. Staging of Primary Tumours

The staging of primary tumours can be separated into the assessment of the local tumour site and then the assessment for metastatic disease. As described above, MRI is the chief modality to assess both bone and soft tissue sarcoma for local extent as well as the tumour's relationship to the nerves, arteries, veins, destruction of bony cortex, and local invasion of the other organs. MRI is clearly superior to CT; however, for those patients who cannot have an MRI, CT staging is also quite accurate. The multiplanar capability of MRI is more useful for surgical planning. Contrast improves the visibility of tumour necrosis and vessels within a sarcoma. The vast majority of sarcomas of bone and soft tissue typically metastasize to the lungs. As such, the assessment of lung metastasis is performed using multidetector CT. While most pulmonary nodules are easily seen without contrast, the addition of the CT contrast agents is helpful in assessing tumours adjacent to vascular structures as well as for the assessment of adenopathy in the chest. There are some sarcomas which have unusual metastatic pathways to lymph nodes such as epithelioid sarcoma and synovial sarcoma. Additionally, leiomyosarcomas and myxoid liposarcomas can metastasize to the intra pelvic or abdominal lymph nodes, bone, liver, and peritoneum. The second most common site of metastatic disease of sarcomas is to the bone, especially for the most common sarcomas of the bone. Nuclear medicine bone scan has been the typical imaging modality for the assessment of bone metastasis. After lung metastasis, spread to bone is common for osteosarcoma and Ewing's and other aggressive soft tissue sarcomas such as leiomyosarcomas and rhabdomyosarcomas. While MRI is considered most sensitive and specific for the local assessment of a bone sarcoma, it is nearly impossible to adequately image the entire appendicular and central axial skeleton with MR imaging. The time would be extensive and most patients could not tolerate the long MR scanning time. Shortened MR protocols to two sequence whole-body scanning have been employed primarily for research assessment but are not commonly the modality of choice for whole-body screening for

bone metastasis. The sensitivity and accuracy of total body nuclear bone scanning is effective from both a clinically tolerated perspective and practical cost and time perspective. Recent total body nuclear bone scanning technique for metastatic disease has been improved by the replacement of the most commonly used bone scan agent methylene diphosphonate (MDP). In years past the typical bone scan agent used was technetium MDP. In many imaging centres, the technetium MDP agent is being replaced by sodium fluoride. The advantage of these sodium fluoride bone scanning agents is that in addition to the whole-body scanning, low-dose combined CT can be performed to improve the spatial resolution of the location of the lesion as well as improve specificity by differentiating increased activity related to arthritis adjacent to the joint versus a tumour adjacent to a joint. There is some concern the sodium fluoride SPECT-CT may be too sensitive with false-positive studies as compared to technetium MDP. The other evolving technology which may replace nuclear medicine bone scan and basic CT scanning of the body is the use of a combined high-resolution diagnostic CT with PET-CT. The study is performed using fluorodeoxyglucose (FDG) as the most commonly used agent. There are other agents which have been utilized, including radioactive carbon-11, nitrogen-13, oxygen-15, or rubidium-82. However, in clinical practice, these other agents are rarely utilized. PET-CT with high- resolution diagnostic CT allows the areas of greatest activity to be visualized on a high-resolution CT scan as well. The combination of detecting the areas of greatest uptake with the multidetector CT scanner allows precise localization of uptake within specific structures detected on CT. For example, a small or normal-sized lymph node seen on CT with a very high degree of specific uptake value (SUV) is likely pathologic. Most normal organs and lymph nodes have a low degree of activity (SUV < 3), whereas high-grade tumours typically have an uptake (SUV > 5). But this is a gross simplification because acute inflammation can have a high degree of uptake, whereas a low-grade sarcoma can have a low degree of uptake; this is a source of confusion for referring clinicians, nuclear medicine physicians, and radiologists. Knowing the type and grade of a sarcoma can be very helpful in assessing what the value of a low degree of uptake in a specific location means. There are papers that would suggest that the SUV max of a primary sarcoma is an independent prognostic factor for long-term survival. While the high-resolution CT and the PET-CT are performed in one setting, the two components, including the PET and the CT images, are fused and co-registered together. It is also possible for a PET study to be co-registered or fused with an outside-referring facility CT or MRI study performed shortly before or after the MR study. However, to improve the accuracy of the fusion or co-registration, it is best performed at the same setting so as to not have other factors such as exact body positioning come into play. PET-CT, in some cases, may replace the need to perform a bone scan. For example, in the staging of Ewing's sarcoma, lytic bone lesions are better depicted by PET-CT. On the other hand, plastic bone lesions are better detected with traditional Tc-MDP bone scan. In the past, PET-CT has had limited

coverage by payers including Medicare and Medicaid and other large third-party payers. Fortunately, new guidelines for the coverage of oncology FDG PET-CT now provide more widespread coverage of most malignancies, including bone and soft tissue sarcomas. Exceptions to the initial staging and diagnosis use of PET-CT exclude staging for prostate, breast, cervix, and melanoma (Centers for Medicare & Medicaid Services (CAG-00181R4)). There is increasing literature to support PET-CT for high-grade tumours such as Ewing's sarcoma as the more appropriate test to stage these tumours. PET-CTs for other common tumours, such as early-stage colorectal and renal cancers, are not usually approved. Furthermore, inpatient PET-CTs in many hospitals are not covered because of the DRG-related cost issues; therefore, hospitals are typically not willing to absorb the cost related to an inpatient stay. Furthermore, most PET-CT scans are limited in frequency of usually not more often than one every 6 months. For a fast changing tumour, this is a significant restriction on tumour assessment. Undoubtedly new proven evidence-based medicine supporting the valuable role of PET-CT will increase the type of tumours that are covered for this study.

2.5.4.1. Intrathecal Contrast Enhanced CT Scan

This test uses contrast dye to better visualize the spinal canal and nerve roots in the spine. It may be used to help diagnose back problems such as spinal stenosis, particularly in patients with pacemakers or others who cannot have an MRI. The physician applies a numbing medication to the skin, which may sting for several minutes. The doctor uses X-ray guidance to inject a very low dose of contrast fluid (dye) into the spinal fluid. The CT scan is then administered. (See Computed Tomography.) Although no special preparations are required, strict bed rest is necessary for at least 24 hours after the test to prevent spinal headaches. These severe headaches can occur because some of the fluid that surrounds the brain and spinal cord may leak out through the injection site. The test itself may take several hours because it may take that long for the dye to reach the area of interest.

Angiography:

Angiography or arteriography is a medical imaging technique used to visualize the inside, or lumen, of blood vessels and organs of the body, with particular interest in the arteries, veins, and the heart chambers. This is traditionally done by injecting a radio-opaque contrast agent into the blood vessel and imaging using X-ray based techniques such as fluoroscopy.

The word itself comes from the Greek words "angeion" - vessel, and "graphein" - to write or record. The film or image of the blood vessels is called an angiography, or more commonly an angiogram. Though the word can describe both an arteriogram and a venogram, in everyday usage

the terms angiogram and arteriogram are often used synonymously, whereas the term venogram is used more precisely.

The term angiography has been applied to radionuclide angiography and newer vascular imaging techniques such as CT angiography and MR angiography. The term isotope angiography has also been used, although this more correctly is referred to as isotope perfusion scanning.

Technique:

Depending on the type of angiogram, access to the blood vessels is gained most commonly through the femoral artery, to look at the left side of the heart and at the arterial system; or the jugular or femoral vein, to look at the right side of the heart and at the venous system. Using a system of guide wires and catheters, a type of contrast agent (which shows up by absorbing the X-rays), is added to the blood to make it visible on the x-ray images.

The X-ray images taken may either be still, displayed on an image intensifier or film, or motion images. For all structures except the heart, the images are usually taken using a technique called digital subtraction angiography or DSA. Images in this case are usually taken at 2–3 frames per second, which allows the interventional radiologist to evaluate the flow of the blood through a vessel or vessels. This technique "subtracts" the bones and other organs so only the vessels filled with contrast agents can be seen. The heart images are taken at 15–30 frames per second, not using a subtraction technique. Because DSA requires the patient to remain motionless, it cannot be used on the heart. Both these techniques enable the interventional radiologist or cardiologist to see stenosis (blockages or narrowing) inside the vessel which may be inhibiting the flow of blood and causing pain.

After the procedure has been completed, if the femoral technique is applied, the site of arterial entry is either manually compressed, stapled shut, or sutured in order to prevent access-site complications.

2.5.5. Arthrography

Arthrography is often used to help diagnose the cause of unexplained joint pain. A contrast iodine solution is injected into the joint area to help highlight the joint structures, such as the ligaments, cartilage, tendons and joint capsule. Several X-rays of the joint are taken, using a fluoroscope, a special piece of X-ray equipment that immediately shows the image. You may be asked to fast prior to the exam. During the examination, you may be asked to move the joint into various positions as the images are taken. It is normal to experience some discomfort or tingling during the procedure. If

you are or may be pregnant, or are allergic to iodine or shellfish, notify your physician; you may be at a higher risk of complications.

2.5.6. Discography

Discography is a test used to determine whether the discs, the cushioning pads that separate the bones of the spine, are the source of back pain. It may be performed before surgery to positively identify the painful disc(s).

Before the procedure begins, you will be given antibiotics and relaxation medications through an IV line. Medication is used to numb the skin over the test site. During the procedure, the doctor inserts a needle into one or more discs and injects a contrast dye. You'll feel pain when the dye is introduced into the problem disc. Afterward, a CT scan will show any changes in the disc size or shape. You may experience some muscle discomfort after the procedure; your doctor can prescribe pain relievers to ease the discomfort.

No special preparations are required for this test. However, you should not take any pain relievers or anti-inflammatory medications on the day of the procedure.

2.5.7. Magnetic Resonance Imaging (MRI)

An MRI (magnetic resonance image) uses magnetic fields and a sophisticated computer to take high-resolution pictures of your bones and soft tissues, resulting in a cross-sectional image of your body (See figure No 37, 38). It can be used to help diagnose torn muscles, ligaments and cartilage, herniated disks, hip or pelvic problems and other conditions. As with a CT scan, you lie on a table that slides into the tube-shaped MRI scanner. The MRI creates a magnetic field around you, then pulses radio waves to the area of your body to be pictured. The radio waves cause your tissues to resonate. A computer records the rate at which your body's various parts (tendons, ligaments, nerves) give off these vibrations, and translates the data into a detailed, two-dimensional picture. You won't feel any pain while undergoing an MRI, but the machine may be noisy. An MRI takes 30 to 90 minutes, and is not available at all hospitals. Tell your doctor if you have implants, metal clips or other metal objects in your body before you undergo an MRI scan.

Figure No. 39, 40 MRI machine

2.5.8. Ultrasonography

Definition: Ultrasound is sound at frequencies greater than 20 kHz. In air at atmospheric pressure, ultrasonic waves have wavelengths of 1.9 cm or less.

Musculoskeletal ultrasound is used to examine tendons, muscles, nerves, ligaments, soft tissue masses, and bone surfaces by linear prob. It is very helpful in diagnosing ligament sprains, muscles strains and joint pathology.

Hip ultrasound uses sound waves to produce pictures of muscles, tendons, ligaments, joints, bone and soft tissues of the hip (See figure No 39).. It is used to help diagnose abnormalities and may be used in infants to check for developmental dysplasia of the hip. Ultrasound is safe, non-invasive, and does not use ionizing radiation.

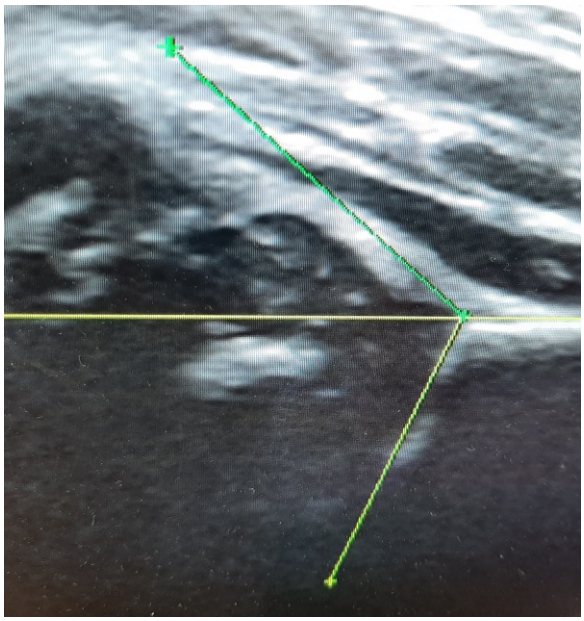

Figure No. 41 Hip Ultrasound for new-born

Ultrasound is an alternative to x-ray imaging in detecting fractures of the wrist, elbow and shoulder for patients up to 12 years (Fracture sonography). Ultrasound can also be used for guidance in muscle or joint injections, aspiration of cyst, such as in ultrasound-guided hip joint injection. This is the same kind of test as the Doppler ultrasound, but without the audio effect (See figure No 40, 41).

Figure No. 42, 43 Ultrasound Machine

2.5.8.1. Doppler Ultrasound

An orthopaedist who suspects that you have a blockage in the blood vessels of your legs or arms may prescribe an ultrasound test. An ultrasound uses high-frequency sound waves that echo off the body. This creates a picture of the blood vessels. The Doppler audio system transmits the "swishing" sound of the blood flow. This is a non-invasive test that has no side effects.

A clear jelly is applied to the skin over the blood vessels being tested. The technician uses a sensor that looks like a microphone. The sensor is placed against the skin and moved up and down across

the area being tested. The technician will apply pressure every few inches to see if the blood vessels change their shape. The test takes about 30 minutes, and most people experience no pain or discomfort.

2.5.9. Dual-Photon Absorptiometry (DPA)

Dual-photon absorptiometry (DPA), a test for osteoporosis, has been mostly replaced by dual-energy X-ray absorptiometry (DEXA) (See figure No 42). DPA measures bone density in the spine, hip, or total body using a photon beam. Although accurate for predicting fracture risk, precision is poor.

Figure No. 44 Densitometry machine

2.5.9.1 Dual-Energy X-ray Absorptiometry (DEXA)

Dual-energy X-ray absorptiometry (DEXA) is the most widely used test for measuring bone density. It can accurately and precisely monitor changes in bone density in patients with osteoporosis who are undergoing treatments. This machine takes a picture of the bones in the spine, hip, total body and wrist and calculates their density. It is painless and non-invasive, requiring no special preparations.

For this exam, you lie on a padded table while the X-ray scanning machine moves over your body to capture images of your hip, spine or entire body. The exam takes about 20 minutes to complete, and the radiation dosage from the X-ray is less than that used for a chest X-ray. Your bone density and risk of fracture are compared to the "normal" range for people your age as well as to the maximum bone density possible.

2.5.9.2. Peripheral Bone Density Testing

You've probably seen portable devices that determine bone mineral density at sites such as the wrist, the fingers, or the heel. Because they are small and cost less than other methods of testing bone density, these devices are frequently used for large-scale osteoporosis screenings. However, bone density varies among different skeletal sites, and bone density may be normal at one site and low at another site. Because these devices only test bone density in a specific site, they may miss indications of osteoporosis in other skeletal areas. In early postmenopausal years, bone density in the spine decreases first, and bone density at other sites does not begin to coincide until about age 70. Although these devices are considered accurate, they may not be precise enough to monitor patients undergoing treatment for osteoporosis. So, even if peripheral bone density is "normal," you may still need a more extensive bone density test to rule out osteoporosis (See figure No 43).

Figure No. 45 Peripheral Bone Density

2.5.9.3. Quantitative Computed Tomography

Quantitative computed tomography (QCT) is used to measure bone mineral density (BMD) for osteoporosis. It is similar to a normal CT scan, but uses a computer software package that determines bone density in the hip or spine. This technique provides for true three-dimensional imaging and reports BMD as true volume density measurements. This enables the physician to focus on a particular area. QCT uses a higher dose of radiation than the standard test for osteoporosis, the dual-energy X-ray absorptiometry test, and may also be more expensive. (See Computed Tomography, Dual-Energy X-ray Absorptiometry.)

2.5.10. Electromyography

An electromyography (EMG) records and analyses the electrical activity in your muscles. It is used to learn more about the functioning of nerves in the arms and legs. For example, a fracture of the

upper arm bone (humerus) may tear or pinch the radial nerve. An EMG can be used to identify the damage if nerve function doesn't return within 4 months of the injury (nerve conduction study). During an EMG, small, thin needles are placed in the muscle to record the electrical activity. When the needles are inserted, you may feel some pain and discomfort. The doctor will ask you to relax the muscle and then to tense it slightly. The electrical signals generated by your muscle are broadcast on a TV-like screen. When the needles are removed, you may experience some soreness and bruising, but this will disappear in a few days. There are no long-term side effects. If you are taking blood-thinning medications, have lung disease or are at risk for infection, tell the physician who is conducting the test. On the day of the test, do not put any lotions or creams on the area to be tested and do not wear any jewellery. Usually, you can get the results immediately after the test.

2.5.10.1. Nerve Conduction Study (NCS)

Nerve conduction studies are often done along with an electromyogram to determine if a nerve is functioning normally. It may be recommended if you have symptoms of carpal tunnel syndrome or ulnar nerve entrapment. The doctor conducting the test will tape wires (electrodes) to the skin in various places along the nerve pathway. Then the doctor stimulates the nerve with an electric current. As the current travels down the nerve pathway, the electrodes placed along the way capture the signal and measure its speed. In healthy nerves, electrical signals can travel at speeds of up to 120 miles per hour. If the nerve is damaged, however, the signal will be slower and weaker. By stimulating the nerve at various places, the doctor can determine the specific site of the injury. Nerve conduction studies also may be used during treatment to test the progress being made. Although you may initially be startled by the suddenness of the stimulation, it is not usually painful and most people are comfortable during the testing procedure. The shock is similar to one received when you touch a doorknob after walking across carpeting.

2.5.11. Flexibility Tests

Flexibility tests are used to measure the range of motion in a joint and are often part of the physical examination. They may be used to help determine whether you have a muscle imbalance or arthritis in a joint. They may also be used to help determine the progression of a condition such as shoulder impingement or a sprain. There are several different kinds of flexibility tests, geared to specific joints and muscles. Your doctor may ask you to reach or bend or to move the affected extremity in a certain way. No preparation is required, and normally these tests are not painful.

2.5.12. Joint Aspiration and Analysis

Joint aspiration may be both a diagnostic test and a treatment option. In conditions such as bursitis, there is a fluid build-up that results in swelling and pressure. A similar fluid build-up around the joints can occur with injuries and arthritis.

Aspiration, or removing the fluid through a syringe, can reduce swelling and relieve pressure. The doctor will swab the skin with an antibacterial solution before inserting the aspirating needle. You may feel some pressure and pain as the needle is inserted, but this should be relieved as the fluid is removed.

After the test, your doctor may send the fluid to a laboratory for analysis. In an injury situation, there may be blood present in the fluid or fat droplets from bone marrow, which indicates the presence of a fracture. The analysis can also determine if the fluids result from an infection or an inflammatory response.

2.5.13. Muscle Tests

Because muscles are soft tissues, they do not appear on X-rays. So muscle testing is an important part of the physical examination. Weakness in a muscle may indicate injury to the tendons that connect the muscle to bone, injury to the nerves that innervate the muscle, or a generalized weakness of the muscle itself from disuse.

To test the strength of your muscles, your physician may ask you to move in certain ways while he or she applies a resistive force. For example, your physician may ask you to sit in a chair and then attempt to raise one knee as the doctor presses down on your upper leg. Or, your physician may hold your elbow at a 90º angle and ask you to bend your wrist down. Measuring grip strength by asking you to squeeze the doctor's hand is another type of muscle test.

Assessment of muscle power

The assessment of muscle power is a key part of examination of the upper or lower limbs by using muscle power scale (MRC)

Score	Discerption
0	No contraction
1	Flicker or trace of contraction
2	Active movements, with gravity elimination
3	Active movements against gravity
4	Active movements against gravity and resistance
5	Normal power

Assessment of muscle tone

Muscle tone is the maintenance of partial contraction of a muscle, important for generating reflexes, maintaining posture and balance, and controlling proper function of other organ systems. Tone is controlled by the sensory muscle spindle, which measures muscle stretch.

Tone is often easily checked by having the patient stand with his/her arms hanging loosely at their side. When the patient's shoulders are moved back and forth or rotated the arms should dangle freely. Increased tone is usually reflected as the arms being held stiffly both in the standing position and when walking.

2.5.14. Stress Tests

Stress test measures bones, muscles and connective tissues (ligaments and tendons). Orthopaedists use applied stress to measure their response (heel, ankle, elbow).

2.5.15. Scintigraphy of the Musculoskeletal System

Scintigraphy (from Latin ``scintilla" - spark), also known as a Gamma scan, is a diagnostic test in nuclear medicine, where radioisotopes attached to drugs that travel to a specific organ or tissue (radiopharmaceuticals) are taken internally (intravenous) and the emitted gamma radiation is captured by external detectors (gamma cameras) to form two-dimensional images in a similar process to the capture of x-ray images. In contrast, SPECT and positron emission tomography (PET) form 3-dimensional images, and are therefore classified as separate techniques to scintigraphy, although they also use gamma cameras to detect internal radiation. Scintigraphy is unlike a diagnostic X-ray where external radiation is passed through the body to form an image.

Process:

Scintillography is an imaging method of nuclear events provoked by collisions or charged current interactions among nuclear particles or ionizing radiation and atoms which result in a brief, localised pulse of electromagnetic radiation, usually in the visible light range (Cherenkov radiation). This pulse (scintillation) is usually detected and amplified by a photomultiplier or charged coupled device elements, and its resulting electrical waveform is processed by computers to provide two- and three-dimensional images of a subject or region of interest.

Scintillography is mainly used in scintillation cameras in experimental physics. For example, huge neutrino detection underground tanks filled with tetrachloroethylene are surrounded by arrays of photo detectors in order to capture the extremely rare event of a collision between the fluid's atoms and a neutrino.

Another extensive use of scintillography is in medical imaging techniques which use gamma ray detectors called gamma cameras. Detectors coated with materials which scintillate when subjected to gamma rays are scanned with optical photon detectors and scintillation counters. The subjects are injected with special radionuclides which irradiate in the gamma range inside the region of interest, such as the heart or the brain. A special type of gamma camera is the SPECT (Single Photon Emission Computed Tomography). Another medical scintillography technique, the Positron-emission tomography (PET), which uses the scintillations provoked by electron-positron annihilation phenomena.

Bone scintigraphy

A bone scan or bone scintigraphy is a nuclear medicine imaging technique of the bone. It can help diagnose a number of bone conditions, including cancer of the bone or metastasis, location of bone inflammation and fractures (that may not be visible in traditional X-ray images), and bone infection (osteomyelitis) (See figure No 44, 45).

Nuclear medicine provides functional imaging and allows visualisation of bone metabolism or bone remodelling, which most other imaging techniques (such as X-ray computed tomography, CT) cannot. Bone scintigraphy competes with positron emission tomography (PET) for imaging of abnormal metabolism in bones, but is considerably less expensive. Bone scintigraphy has higher sensitivity but lower specificity than CT or MRI for diagnosis of scaphoid fractures following negative plain radiography.

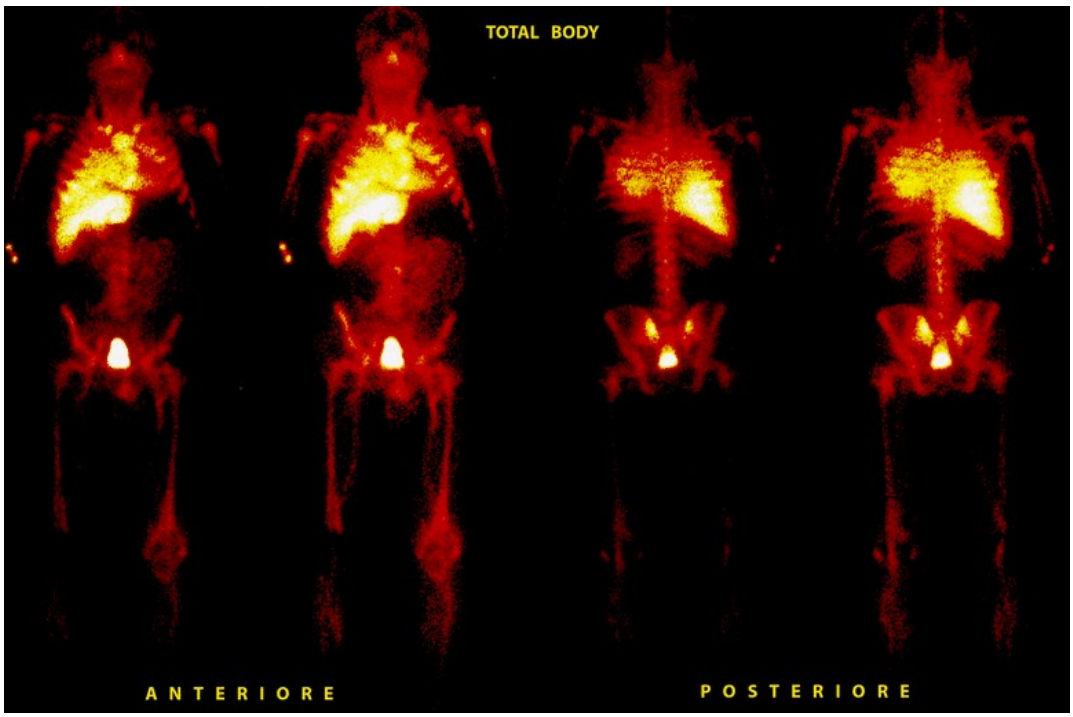

Figure No. 46 Lung scintigraphy result

Figure No. 47 Scintigraphy result

History:

Some of the earliest investigations into skeletal metabolism were carried out by George de Hevesy in the 1930s, using phosphorus-32and by Charles Pecher in the 1940s.
In the 1950s and 1960s calcium-45 was investigated, but as a beta emitter proved difficult to image. Imaging of positron and gamma emitters such as fluorine-18 and isotopes of strontium with rectilinear scanners was more useful. Use of technetium-99m (99mTc) labelled phosphates, diphosphonates or similar agents, as in the modern technique, was first proposed in 1971.

Clinical indications:

Oncological indications – Primary tumours (e.g. Ewing's sarcoma, osteosarcoma) – Staging, evaluation of response to therapy and follow-up of primary bone tumours
Secondary tumours: (metastases) Staging and follow-up of neoplastic diseases Distribution of osteoblastic activity prior to radio metabolic therapy (89Sr, 153Sm-EDTMP, 186Re-HEDP)
Indications for non-neoplastic diseases:
Osteomyelitis
Perthes' disease, avascular necrosis
Metabolic disorders (Paget's disease, osteoporosis) – Arthropathies – Fibrous dysplasia and other rare congenital conditions– Stress fractures, shin splints– Loose or infected joint prosthesis– Low back pain, sacro-iliitis– Reflex sympathetic syndrome– Any other bone injuries.

Precautions:

Pregnancy (suspected or confirmed). In the case of a diagnostic procedure in a patient who is known or suspected to be pregnant, a clinical decision is necessary to weigh the benefits against the possible harm of carrying out any procedure.
Breast-feeding should be discontinued and milk expressed and discarded when possible for 24 h (and at least for 4 h) post radiopharmaceutical administration).

Principle:

The most common radiopharmaceutical for bone scintigraphy is 99mTc with methylene diphosphonate (MDP). MDP adsorbs onto the crystalline hydroxyapatite mineral of bone. Mineralisation occurs at osteoblasts, representing sites of bone growth, where MDP (and other diphosphates) "bind to the hydroxyapatite crystals in proportion to local blood flow and osteoblastic activity and are therefore markers of bone turnover and bone perfusion".

The more active the bone turnover, the more radioactive material will be seen. Some tumours, fractures and infections show up as areas of increased uptake.

Technique:

In a typical bone scan technique, the patient is injected (usually into a vein in the arm or hand, occasionally the foot) with up to 740 MBq of technetium-99m-MDP and then scanned with a gamma camera, which captures planar anterior and posterior or single photon emission computed tomography (SPECT) images. In order to view small lesions SPECT imaging technique may be preferred over planar scintigraphy. In a single phase protocol (skeletal imaging alone), which will primarily highlight osteoblasts, images are usually acquired 2–5 hours after the injection (after four hours 50–60% of the activity will be fixed to bones).A two or three phase protocol utilises additional scans at different points after the injection to obtain additional diagnostic information. A dynamic (i.e. multiple acquired frames) study immediately after the injection captures perfusion information. A second phase "blood pool" image following the perfusion (if carried out in a three phase technique) can help to diagnose inflammatory conditions or problems of blood supply.
A typical effective dose obtained during a bone scan is 6.3 millisievert (mSv).

Full body

Examples are gallium scans, indium white blood cell scans, iobenguane scan (MIBG) and octreotide scans. The MIBG scan detects adrenergic tissue and thus can be used to identify the location of tumours such as pheochromocytomas and neuroblastomas (See figure No. 46).

.

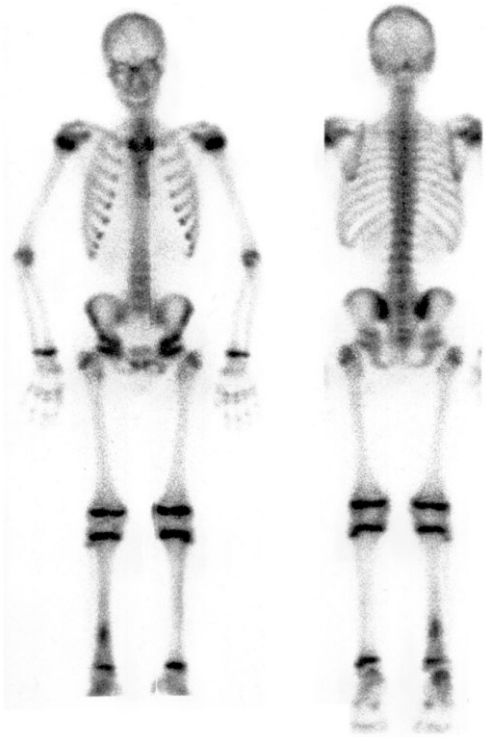

Figure No. 48 Indium-111 WBC scan

The indium white blood cell scan, is a nuclear medicine procedure in which white blood cells (mostly neutrophils) are removed from the patient, tagged with the radioisotope Indium-111, and then injected intravenously into the patient. The tagged leukocytes subsequently localize to areas of relatively new infection. The study is particularly helpful in differentiating conditions such as osteomyelitis from decubitus ulcers for assessment of route and duration of antibiotic therapy.

In imaging of infections, the gallium scan has a sensitivity advantage over the indium white blood cell scan in imaging osteomyelitis (bone infection) of the spine, lung infections and inflammation, and in detecting chronic infections. In part, this is because gallium binds to neutrophil membranes, even after neutrophil death, whereas localization of neutrophils labelled with indium requires them to be in relatively good functional order. However, indium leukocyte imaging is better at localizing acute (i.e., new) infections, where live neutrophils are still rapidly and actively localizing to the infection, for imaging for osteomyelitis that does not involve the spine, and for locating abdominal and pelvic infections.

Both the gallium scan and indium-111 white blood cell imaging may be used to image fever of unknown origin (elevated temperature without an explanation). However, the indium leukocyte scan will localize only to the approximately 25% of such cases which are caused by acute infections, while gallium is more broadly sensitive, localizing to other sources of fever, such as chronic infections and tumours. Gallium may be a better choice for spleen study because gallium does not normally accumulate in the spleen.

2.6. Histology and cytology investigations

Purpose of the biopsy is to confirm a suspected diagnosis, aggressive bone or soft tissue lesions.

Types of biopsy are:

Fine Needle Aspiration (FNA) provides cytologic (cellular) specimens, frequently used for carcinoma, not typically used for sarcoma.

Core biopsy (Tru-cut) allows for tumor structural examination, and can evaluate both the cytologic and stromal elements of the tumor, frequently used for sarcoma.

Incisional biopsy small surgical incision carefully placed to access tumor without contamination of critical structures, select indications: small, superficial soft tissue masses.

Excisional biopsy for small, superficial soft tissue masses (See figure No. 47, 48, 49).

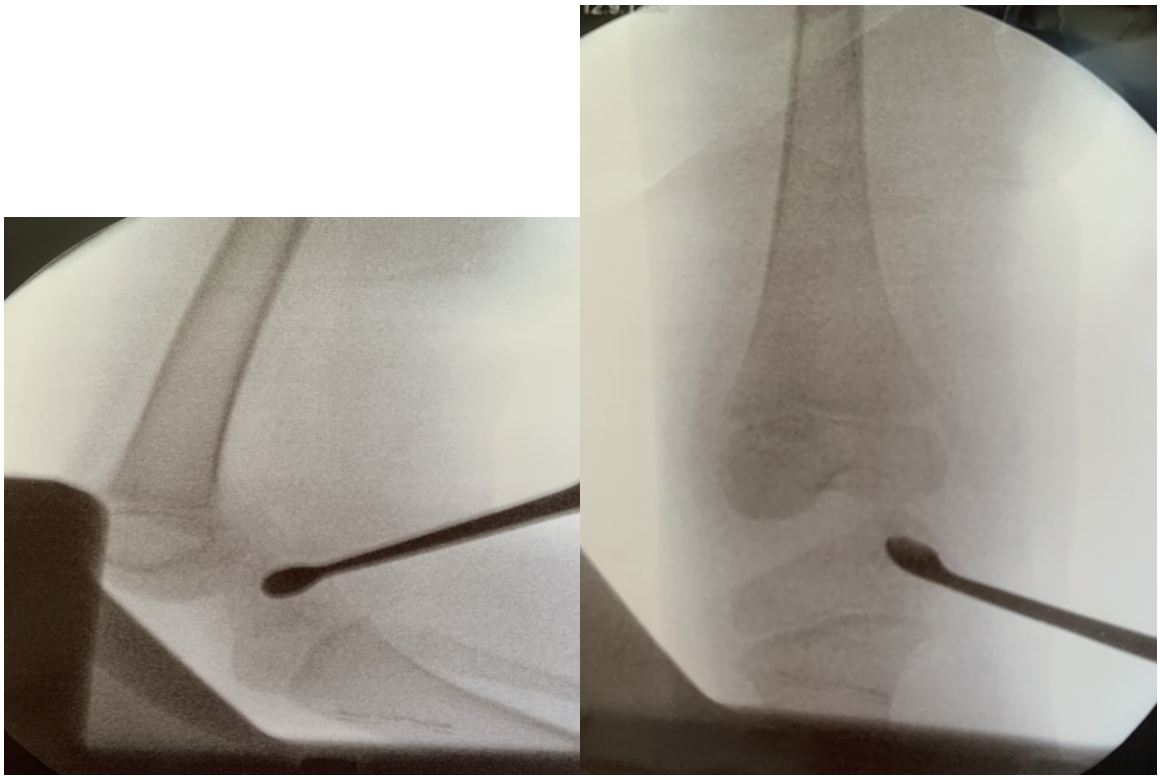

Figure No. 49, 50 Incisional biopsy under fluoroscopy

Figure No. 51 Incisional biopsy

2.7. Diagnostic arthroscopy

A diagnostic joint arthroscopy is a procedure to look inside the joint to check for disease or damage inside your knee. It can be done for any joint to confirm a suspected diagnosis.

2.8. Sample of patient's documentation (state exam)

Patient's name: XY

Date of birth: DD.MM.20YY **Age:**

Gender: Female/Male

Weight: 79 kg **Length:** 173 cm **BMI:**

Hospitalization: From DD.MM.20YY To DD.MM.20YY

Family history: Patient has no brother or sisters. His father at the age of 5,5 years old overcame meningitis, his mother suffers from asthma. No other chronic diseases in the family were mentioned. Personal history: Child of the first pregnancy. The pregnancy was without any complaint. He was born at the 44th week of gestation with breech delivery. His birth weight was 3000 gr and his height was 48 cm. Mother had hepatitis C, and was positive for HbsAg so intrapartum prevention was necessary. At the 7th month of age, the patient was examined for hepatitis-C but the anti-HCV test was negative. The breastfeeding period was short. Vaccination was done according to the routine Slovak Republic Schedule. He was hospitalized on 02/2012 and on 06/2012 diagnosed both times with obstructive bronchitis. He has never undergone any operation, while no injury has been reported. He was not infected by varicella and he did not come in contact with any infected person. Social anamnesis: Social case Allergic anamnesis: Allergies to medications, food-stuff or other substances have not been reported. Drug history: Patient received Vigantol, Ventolin spray from 20.8.2021 until 22.08.2021 at 11:00 o'clock daily. Present complaint: 9,5 month old child was admitted with recurrent obstructive bronchitis occurring for the second time. Last time he was hospitalized in July and was dismissed on 18.07.2021 On 22.08 he was admitted being already four days sick with cough, decreased respiratory rate and afebrile state until the date of admission. His mother mentioned that the inhalation of prescribed ventolin did not improve the condition. Dyspnoe is worsening during night time. The day of admission (22.08.2021) was hospitalized with objective findings of obstructive bronchitis without dyspnoe. He is eating and drinking without difficulties while no vomiting and diarrhea have been reported and his urination is done without difficulties.

Vital signs: Temperature: 36,8°C rectally/ axillary/ orally/ non-contact

Heart rate: 74/ min

O2 saturation: 98%

Respiratory rate: 55/min

Status present generalis (SPG): 69 years old male patient, conscious. Turgor is normal. Also did not present any sign of icterus or cyanosis. There were no skeletal deformities. The musculature is normotrophic but hypotonic…….

Status present localis: Lt. hip: The limps were symmetrical without any sign of deformity, oedema, without any movement limitation. Pulsation of femoral arteries is palpable bilaterally. Length is similar……

Laboratory tests:

Complete cell count (CBC): value Leukocytes 11,1* 10^3/ul Erythrocytes 4.25*10^6/ul Hemoglobin 11.3 g/dl Hematocrit 32.8% MCH 26.6pg MCV 77.2 fl Lymphocytes% 60,6 Thrombocytes 442*10^9/l MXD% 13.2% Neutrophils% 26.2% MXD# 1.5*10^3/ul Neutrophil# 2.9*10^3/ul Lymphocytes# 6,7*10^3/ul

Biochemical results Value CRP 4 mg/dl ALT 0,44 ukat/l Creatinine 20 umol/l Glucose 5,6 mmol/l Substrates value Urea 3,6 mmol/l Uric acid 211 umol/l Ions Value Na 141 mmol/l K 4,98 mmol/l CL 104 mmol/l Urinalysis Result PH 7,0 Proteins + Glucose Negative Urobilinogen Negative Bilirubin Negative Ketone bodies Negative Erythrocytes Negative Leukocytes Negative Nitrates Urine sedimentation value: Erythrocytes 1-3 Leukocytes 7-9 Bacteria Positive Amorphous salts Positive Mucous fibers Positive Acid base Value Control next day pH 7,38 7,43 pCO2 3,7 3,6 kPa BE -7,1 -5,0 mmol/l HCO3 act 16,2 17,6 mmol/l pO2 8,9 8,8 kPa sat. O2 93 94%

Cultivation results: Sample from tonsil: alpha-hemolytic streptococcus, non-pathogenic, Neisseria, Staphylococcus species Sample from nose: ampicillin resistant Staphylococcus Aureus Other examinations

Stool examination: Rotavirus, Adenovirus, parasites

Diagnosis: Arthritis,

Differential Diagnosis: fracture, arthrosis of Rt. Knee, Lt. wrist….

Therapy: Pain relief medication: Ibuprofen (Nurofen) Steroids local, SADO – slow acting drugs in osteoarthritis, SYSADOA – symptomatic slow acting drugs in osteoartrosis, Probiotics.

Diet: 3, 9, 13, 12, 2, 1, NPO

3. Principles of Injection in Orthopaedic surgery (Joints and soft tissue)

In Orthopaedic surgery joint and soft tissue injections is a procedure used in the diagnostic or treatment. Intra-articular administration of cortisone and hydrocortisone began in 1950-51. The technique is also used to withdraw excess fluid from the joint.

3.1. Indications for joint injection

- Inflammatory arthritis
- Crystalloid arthropathies: gout, pseudogout
- Synovitis (See figure No 50)
- Advanced osteoarthritis
- Trauma

Figure No. 52 right knee effusion

3.2. Indications for soft tissue injection

- Tenosynovitis - de Quervain's tenosynovitis, trigger finger
- Elbow epicondylitis
- Bursitis - olecranon bursitis, housemaid's knee, Achilles bursitis
- Tendinopathies - Achilles tendinopathy: corticosteroid injection is beneficial in the short term for the treatment of tendinopathies but may be worse than other treatments in the intermediate and long term
- Nerve compression - carpal tunnel syndrome
- Plantar fasciitis
- Tendinopathies
- Ganglion cysts
- Neuromas

- Entrapment syndromes
- Fasciitis

3.3. Before Joint and soft tissue injection

- Thorough history and examination; investigations as indicated: carefully consider the differential diagnosis and avoid inappropriate injections.
- Consider other treatment options - non-steroidal anti-inflammatory drugs (NSAIDs), physiotherapy.
- Explain the procedure to the patient.
- Informed consent: ensure the patient is fully aware of the potential benefits and risks of the procedure.
- Know the anatomy and never attempt any injections in the vicinity of known nerve or arterial landmarks.
- Never inject into the substance of a tendon.

3.4. Procedure of Joint and soft tissue injection

- Thoroughly clean the area and use a totally aseptic technique.
- Always withdraw the syringe back first to ensure not injecting into a blood vessel.
- Inject slowly but with constant pressure (see figure No. 51, 52, 53).
- If local anaesthetic is required, inject local anaesthetic first; wait 3-5 minutes and then use a larger-bore needle to inject the corticosteroid. However, it may be preferred to inject the local anaesthetic and steroid in combination and so use just one needle.
- Send a joint aspirate for microscopy and analysis.
- Give as few injections as possible to settle the problem; no more than two in any single joint.

Figure No. 53 Shoulder joint effusion aspiration

Figure No. 54 Ultrasound-Guided Aspiration

3.5. Arthrocentesis Joint Aspiration

Joint aspiration is a procedure to remove fluid from the space around a joint. It is done using a needle and syringe. This is often done to relieve swelling or to get fluid for analysis to diagnose a joint disorder or problem. It is done with a local anesthetic to reduce pain.

Joint aspiration is most often done on the knee. But fluid can also be removed from other joints. These include the hip, ankle, shoulder, elbow, and wrist joints.

Other related procedures may be used to help diagnose joint problems. These include X-ray, bone scan, MRI, CT scan, arthroscopy, and arthrography.

Joint aspiration we have done to diagnose and treat joint disorders. These conditions may be diagnosed by testing the fluid:

- Gout
- Various types of arthritis
- Joint infection

Joint aspiration can also be done to remove a large amount of fluid around a joint. Sometimes bursitis (inflammation of the bursa) causes fluid to collect near a joint. Removing the fluid will decrease the pressure. It can relieve pain and improve movement of the joint. A medicine may be injected after removal of the fluid. This is done to help treat tendonitis or bursitis.

Aspirate analysis

Diagnosis	Appearance	Viscosity	Special findings
Normal	Clear - yellow	High	
Traumatic	Straw - red	High	Blood
Rheumatoid arthritis (RA)	Cloudy	Low	Latex RA haemagglutination titre
Osteoarthritis	Clear - yellow	High (normal)	Possibly small fragments of cartilage
Gout	Cloudy	Decreased	Monosodium urate crystals (needle-like)
Pseudogout	Cloudy	Decreased	Calcium pyrophosphate crystals (rhomboid)
Septic arthritis	Turbid or purulent	Low	Culture positive
Tuberculous arthritis	Cloudy	Low	Culture positive for acid-fast bacillus

3.6. Image-Guided Biopsy

Over the last decade, there has been an increasing role in image-guided biopsy for accurate tissue diagnosis. Routine use of open surgical biopsy in many cases is neither cost-effective nor safer. In the past, the most common reason for open surgical biopsies was that radiologists were untrained in sarcoma biopsies, had performed few of them, and universally failed to obtain enough tissue. In large cancer centers where musculoskeletal radiologists work closer with their surgical oncologists, the biopsies can be performed by very experienced interventional musculoskeletal radiologists who understand and respect the importance of surgical planes of resection. When performed with appropriate CT or ultrasound guidance and with identification of important neurovascular structures and large tumour vessels, multiple (6–10) large cores can safely be obtained. CT may be more useful for deep bone biopsies. Ultrasound is faster and easily identifies vascular structures and may be preferable for more superficial soft tissue masses. Fine needle aspirates are usually not satisfactory for demonstrating sarcoma micro-architecture, which can be critical to proper classification of the tumour. In our institution we have highly trained cytopathologists who can accurately evaluate the viability versus necrosis/haemorrhage of core biopsy samples. Areas showing haemorrhage or necrotic tumour can be avoided and the biopsy directed to other regions of tumour without utilizing a different puncture site. Using CT guidance, the more aggressive area of bone sarcoma can be identified and selectively biopsied. For example, areas of parosteal osteosarcoma that have a more lytic appearance should be biopsied rather than areas of bland

osteosclerosis. With dedifferentiated chondrosarcomas, the more aggressive areas are more likely to have soft tissue breakthrough and less bland appearing enchondroma chondroid appearance. In addition, CT or ultrasound-guided biopsy can be scheduled the same day or within a day or so of initial discovery. CT or ultrasound-guided needle biopsy does not require general anesthesia or operating room time; CT or ultrasound core biopsies are often done with moderate sedation with IV midazolam and fentanyl. After a needle core biopsy, there are no problems with wound healing and neoadjuvant chemotherapy, or radiation can be started immediately. The likelihood of procedural complications such as hematoma or infection from a needle biopsy in experienced hands should be much less than an open biopsy. The technique of a CT or ultrasound-guided core needle biopsy of a potential sarcoma is different from a CT or ultrasound fine needle biopsy of a primary or metastatic lung or liver cancer. First, the biopsy of a possible sarcoma should be set up to obtain maximal core samples. The most common tumour biopsies of lesions from metastatic lung, breast, colon, or head and neck cancer are usually performed with a 22G needle. The route chosen for the biopsy is usually the "safest." For example, a lung biopsy is performed with the biopsy pathway closest to the pleural surface of the lesion, minimizing the risk of pneumothorax or hemorrhage. The performing interventional radiologist will identify his/her chosen approach at the time of the biopsy. In some cases as few as two or three passes may be diagnostic. Because only a few passes are made with a 22G needle, sedation may not be required. The tissue diagnosis of a primary sarcoma is optimized by maximal core sample size and number. For soft tissue sarcomas, multiple 14 or 16G cores are obtained with a biopsy gun. For lesions near the skin surface that are easily palpable, this can be accomplished in the clinic setting; deeper soft tissue tumours require image CT guidance. Dense or sclerotic bone sarcomas may require a larger 8 or 11G bone needle to penetrate the cortex and penetrate through the sclerotic tumour. Again, multiple large core samples are obtained. Because of the greater size of the needles and the number of needle passes required (four to six versus two or three passes), moderate sedation is required for patient comfort. Additionally, because large needle sizes are being used (8–16G versus 22G needle), the risk of tumour seeding of the tract is increased. Oncologic surgeons typically remove any previous incomplete surgical excision or biopsy tract of a proven sarcoma at the time of definitive surgery. If the core needle biopsy is not performed in the plane of resection, this might result in the need to perform a second incision at the time of resection. While most interventional experts recommend direct consultation with the treating oncologic surgeons and strict adherence to compartmental anatomy, there is a recent article suggesting not all biopsies must be done with strict adherence to compartmental anatomy. This study, however, was performed by a highly skilled large musculoskeletal radiology group with excellent rapport with their surgical oncologists. We recommend all sarcoma biopsies be reviewed with a surgical oncologist before the procedure. For cases of potential sarcoma referred by a general physician, we

consult with our surgical oncologists on a potential approach even if the patient is not known to them. According to Mankin, even today an inappropriate initial biopsy or partial excision of a sarcoma by a general surgeon, orthopedic surgeon, or radiologist is still a common cause of complications resulting in additional surgery or even amputation. This study showed no improvement in mismanagement by initial biopsy or surgical approach over 14 years, and 19 patients required amputation because of improper initial biopsy and surgery. It is still common that orthopaedic oncologists are required to make a second incision at the time of definitive surgery because the initial open surgical or needle biopsy was not done near the expected surgical plane of resection. Newer needles have dramatically improved the quality of core specimens obtained both for bone and soft tissue sarcomas. New bone needles have hand drill bits which allow much easier control and penetration of an intact cortex or sclerotic bone lesions. Many of these needles have just become available in the last several years. In general, for larger sclerotic bone tumours, we use bone core needles between (see figure No. 53, 54).

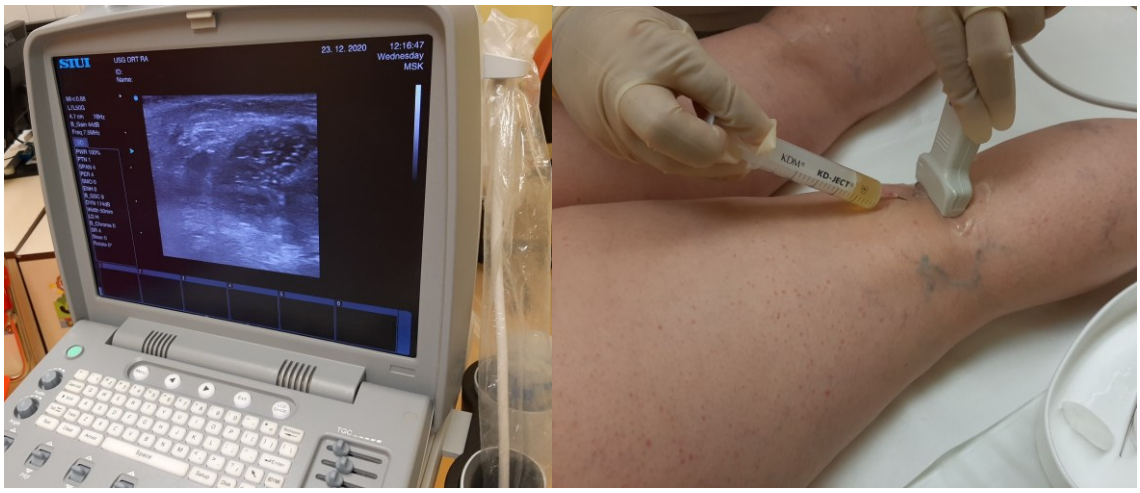

Figure No. 55, 56 Ultrasound-Guided Aspiration of a Baker's Cyst

3.7. Cautions

- Those with diabetes: should closely monitor their blood glucose for two weeks following injection.
- Anticoagulated, bleeding disorder.
- Immunosuppressed.
- Psychogenic pain, severe anxiety.
- Neurogenic disease.
- Active infections (eg, tuberculosis).
- Hypothyroidism.

3.8. Patient advice

- Advise the patient to rest the joint for 1-2 days and to avoid strenuous use for five days.
- Warn the patient that the joint may be painful for a while and advise on use of analgesics.
- Following injection, patients should be warned that they might experience worsening symptoms during the first 24-48 hours (related to a possible steroid flare) which can be treated with ice and NSAIDs. If pain is severe or increasing after 48 hours, seek advice.
- Warn about possible other side-effects. Advise to seek help if systemic side-effects develop suggesting infection.
- Arrange appropriate follow-up.

3.9. Mistakes in joint and soft tissue injections

- Poor technique
- Large dose
- Frequent injections
- Failure to mix and dissolve the medications properly.

3.10. Side-effects

3.10.1. Local Side-effects

- Infection
- Post-injection flares of pain (2-5%); reduced incidence with rest for 24 hours.
- Skin discolouration; improves with time.
- Subcutaneous fat atrophy.
- Bleeding (rare). Soft tissue calcification with repeated injection at the same site
- Joint injury (do not move the needle from side to side within the joint); cartilage damage and osteoporosis: avoid repeated injections (no more than four injections in each location per year).
- Tendon atrophy and rupture (<1%): avoid direct tendon injection.
- Pericapsular calcification (>40%).
- Avascular necrosis.

3.10.2. Systemic Side-effects

- Flushing of skin.
- Temporary impairment of diabetic control.
- Vasovagal reaction.
- Anaphylaxis (rare but adrenaline (epinephrine), etc, should be close at hand).

3.11. Contra-indications

- Infection: septic arthritis, adjacent osteomyelitis, periarticular cellulitis, severe dermatitis, soft tissue infection, sepsis, bacteraemia.
- Increased risk of causing joint infection - immunosuppressed, broken skin over the injection point.
- Trauma: haemarthrosis, fracture.
- Very unstable joint - Charcot joint.
- Impending (scheduled within days) joint replacement surgery.
- Joint prosthesis.
- History of allergy to injectable constituents.
- Poorly controlled diabetes mellitus.
- Uncontrolled bleeding disorder or coagulopathy.

References:

1. Cited 2020 October 18. Available from: https://teachmesurgery.com/examinations/orthopaedic/
2. Cited 2020 October 18. Available from: https://physicaltherapyweb.com/orthopedic-physical-examination-tests/
3. Solomon L, Warwick D, Nayagam S. Apley and Solomon's Concise System of Orthopaedics and Trauma. 4th edition, CRC Press, 2014; pp 504. ISBN 0-340-76373-6.
4. Miller M, Thompson S. Millers Review of Orthopaedics. 7 edition, Elsevier, 2015; pp 904. ISBN 978-1-4160-4093-4.
5. Vojtaššák, J. Ortopédia a Traumatológia. Bratislava: SAP, 2006, 576 pp, ISBN 80-89104-95-9.
6. Mark Dutton, PT. Dutton's Orthopaedic Examination, Evaluation. China: Library of Congress Catalogingand Intervention, Fourth Edition, 2016, 1672 pp, ISBN 978-1-259-58310-0
7. Joshua A. Cleland, Shane Koppenhaver, Jonathan Su. Netter's Orthopaedic Clinical Examination An Evidence-Based Approach. Third edition. 2015, Elesevier, 611 pp, ISBN: 978-0-323-34063-2
8. David J. Dandy, Dennis J. Edwards. Essential Orthopaedics and Trauma. Fifth Edition. 2009, 508 pp, ISBN-13: 978-0443067181
9. MRÁZ, P. a kol. Anatomia ludského teľa I-II. 1. vyd. Bratislava : Slovak Academic Press, 2004, 509 s. ISBN 80-89104-57-6.
10. BARTONÍČEK, J. - HERTA, J. Základy klinické anatomie pohybového aparátu. Praha: Maxdorf, 2004, 256 s. ISBN 80-7345-017-8.
11. DEE, R. et al.: Principles ofo rthopaedic and fractures, 2007, 1522 s. ISBN 0-07-016350-1.
12. Cited 2020 November 21nd . Available from: (https://creativecommons.org/licenses/by-sa/4.0)
13. Cited 2020 November 21nd . Available from: https://www.google.com/search?ei=xfy9X7qZHNGdkgXIkpK4Cg&q=lachman+knee+examination+tests&oq=lachman+knee+examination+tests&gs_lcp=CgZwc3ktYWIQDDoCCAA6BAgAEB46BggAEAgQHjoECAAQDToGCAAQDRAeOggIABAIEA0QHlCHUli9kgFgiaMBaABwAHgAgAHNAYgBwAiSAQU3LjIuMZgBAKABAaoBB2d3cy13aXrAAQE&sclient=psy-ab&ved=0ahUKEwj6j_DRi53tAhXRjqQKHUiJBKcQ4dUDCAw
14. Cited 2020 November 10th . Available from: https://www.physio-pedia.com/
15. Cited 2020 November 11th .Available from: https://en.wikipedia.org/wiki/
16. Cited 2020 November 1st .Available from: https://www.orthobullets.com/

List of Figures

Figure No. 1 discolouration and skin defect 11

Figure No.2 Inflammation 12

Figure No. 3 Lateral flexion of cervical spine to the left side……15

Figure No. 4 Lateral flexion of lumbar spine to the right side…….16

Figure No. 5 sagittal movements of lumbar spine flexion ….16

Figure No. 6 sagittal movements of lumbar spine extention….16

Figure No. 7 Goniometer……..19

Figure No. 8 Shoulder movements……..19

Figure No. 9 Shoulder movements……..19

Figure No. 10 Palpation of lateral epicondyles……26

Figure No. 11 Palpation of medial epicondyles……26

Figure No. 12 Polydactyly …….. 29

Figure No. 13 Polydactyly …… 29

Figure No. 14 Ulnar deviation of wrist……..31

Figure No. 15 radial deviation of wrist……31

Figure No. 16 Flection of wrist……..31

Figure No. 17 Extention of wrist……..31

Figure No. 18 External rotation of hip……. 35

Figure No. 19 Internal rotation of hip……. 36

Figure No. 20 Ortolani test and Barlow test…….38

Figure No. 21 Right knee effusion …….. 40, 75

Figure No 22 Leg deformation …... 41

Figure No 23 Knee hyperextension……..42

Figure No. 24 Anterior drawer test of the knee……..43

Figure No. 25 Posterior drawer test of the knee…….43

Figure No. 26 Stress test of lateral collateral ligament of knee…....44

Figure No. 27 Stress test of medial collateral ligament of knee……44

Figure No 28 ankle plantar flexion ……. 48

Figure No 29 ankle dorsal flexion …….. 48

Figure No. 30 Podoscopic Machine ……. 51

Figure No. 31 Podoscopic Machine ……. 51

Figure No.32 Venepuncture for blood tests ……. 52

Figure No. 33 Venepuncture for blood tests ……. 52

Figure No 34 X-Ray digital Machine …….. 55

Figure No 35 X-Ray digital Machine …….. 55

Figure No 36 X-Ray Beam …….. 56

Figure No. 37 X-Ray of the spine (Scoliosis)……..57

Figure 38 CT machine……. 58

Figure No.39 MRI machine ……. 64

Figure No.40 MRI machine ……. 64

Figure No. 41 Hip Ultrasound for new-born …… 64

Figure No. 42 Ultrasound Machine……65

Figure No. 43 Ultrasound Machine……65

Figure No. 44 Densitometry machine …….. 66

Figure No. 45 Peripheral Bone Density ……. 67

Figure No. 46 Lung scintigraphy result …..... 72

Figure No. 47 Scintigraphy result …..... 72

Figure No. 48 Indium-111 WBC scan..... 75

Figure No. 49 Incisional biopsy under fluoroscopy 76

Figure No. 50 Incisional biopsy under fluoroscopy 76

Figure No. 51 Incisional biopsy 77

Figure No. 52 right knee effusion 80

Figure No. 53 Shoulder joint effusion aspiration……82

Figure No. 54 Ultrasound-Guided Aspiration……82

Figure No. 55 Ultrasound-Guided Aspiration of a Baker's Cyst 85

Figure No. 56 Ultrasound-Guided Aspiration of a Baker's Cyst 85

Examination methods and injection technique in orthopaedics
Academic textbook

Authors:	MUDr. Ahmad Gharaibeh, PhD., MPH Doc. MUDr. Marek Lacko, PhD.
Publisher:	Pavol Jozef Šafárik University in Košice Publishing ŠafárikPress
Year:	2021
Pages:	90
Author's sheets:	4,2
Edition:	first
ISBN	978-80-8152-989-4 (e-publication)